

International Surgery

Rigid and Flexible Bronchoscopy in the Sitting Position A Case Report and Historical Review --Manuscript Draft--

Manuscript Number:	INTSURG-D-25-00021
Full Title:	Rigid and Flexible Bronchoscopy in the Sitting Position A Case Report and Historical Review
Article Type:	Review
Keywords:	tracheobronchoscopy
Corresponding Author:	Raymond Andrew Dieter Jr, M.D., BS, MS Northern Illinois Center for Surgery Naperville, Illinois UNITED STATES
Corresponding Author Secondary Information:	
Corresponding Author's Institution:	Northern Illinois Center for Surgery
Corresponding Author's Secondary Institution:	
First Author:	Raymond Andrew Dieter Jr, M.D., BS, MS
First Author Secondary Information:	
Order of Authors:	Raymond Andrew Dieter Jr, M.D., BS, MS
Order of Authors Secondary Information:	
Abstract:	Laryngotracheobronchial endoscopy techniques and equipment have rapidly advanced since the mid 1800's. Techniques and equipment continue to evolve as do the endoscopists. Older rigid equipment and endoscopy techniques have been rapidly replaced by the current modern flexible and video equipment training programs. Historically, sitting bronchoscopy has been utilized in both diagnostic and treatment situations. Upright positioning was more common when rigid bronchoscopy was the only option. As with many medical advances, older diagnostic and therapeutic techniques frequently are discarded and forgotten. Modifications in equipment have greatly reduced both the need for rigid and the need for the sitting position bronchoscopy. However, sitting or upright bronchoscopy utilization, usually flexible, continues on a limited basis at this time.

Rigid and Flexible Bronchoscopy in the Sitting Position:
A Case Report and Historical Review

by

Raymond A. Dieter, Jr., M.D.
Past President International College of Surgeons
Thoracic and Cardiovascular Surgeon
Northwestern System at Central DuPage (Emeritus)
22W240 Stanton Road
Glen Ellyn, IL 60137 USA
630-858-4561

Heinrich D. Becker, M.D.
Bronchology and Pulmonology
Talstrasse 75
64198 Schriesheim, Germany
+49-6203-660416

George B. Kuzycz, M.D.
Cardiovascular and Thoracic Surgeon
Northwestern System at Central DuPage (Emeritus)
795 Crescent
Glen Ellyn, IL 60137 USA
630-790-1079

Raymond A. Dieter, III, M.D.
CardioThoracic Surgeon
Professor of Surgery and Chief Cardiothoracic Surgery
University of Tennessee Medical Center
1928 Alcoa Highway
Knoxville, Tennessee 37920 USA
865-927-0444

Robert S. Dieter, M.D., R.V.T., A.L.M.
Cardiovascular Medicine
Hines VA
Professor of Medicine
Loyola University
2160 S. First Ave
Maywood, IL 60153
708-216-6400

Rigid and Flexible Bronchoscopy in the Sitting Position:
A Case Report and Historical Review

by

Raymond A. Dieter, Jr., M.D.
Past President International College of Surgeons
Thoracic and Cardiovascular Surgeon
Northwestern System at Central DuPage (Emeritus)
22W240 Stanton Road
Glen Ellyn, IL 60137 USA
630-858-4561

Heinrich D. Becker, M.D.
Bronchology and Pulmonology
Talstrasse 75
64198 Schriesheim, Germany
+49-6203-660416

George B. Kuzycz, M.D.
Cardiovascular and Thoracic Surgeon
Northwestern System at Central DuPage (Emeritus)
795 Crescent
Glen Ellyn, IL 60137 USA
630-790-1079

Raymond A. Dieter, III, M.D.
CardioThoracic Surgeon
Professor of Surgery and Chief Cardiothoracic Surgery
University of Tennessee Medical Center
1928 Alcoa Highway
Knoxville, Tennessee 37920 USA
865-927-0444

Robert S. Dieter, M.D., R.V.T., A.L.M.
Cardiovascular Medicine
Hines VA
Professor of Medicine
Loyola University
2160 S. First Ave
Maywood, IL 60153
708-216-6400

Summary:

Laryngotracheobronchial endoscopy techniques and equipment have rapidly advanced since the mid 1800's. Techniques and equipment continue to evolve as do the endoscopists. Older

rigid equipment and endoscopy techniques have been rapidly replaced by the current modern flexible and video equipment training programs. Historically, sitting bronchoscopy has been utilized in both diagnostic and treatment situations. Upright positioning was more common when rigid bronchoscopy was the only option. As with many medical advances, older diagnostic and therapeutic techniques frequently are discarded and forgotten. Modifications in equipment have greatly reduced both the need for rigid and the need for the sitting position bronchoscopy. However, sitting or upright bronchoscopy utilization, usually flexible, continues on a limited basis at this time.

Keywords: tracheobronchoscopy,

Introduction

Physicians have examined the human orifices - rectum, vagina, urethra, auditory canal, oral and nasal cavities - for centuries. Initially, these openings were only available by direct manual or ocular examination. John Hunter in 1755 kept a dog breathing artificially by cutting in to the trachea and inserting a double lumen bellows after Robert Hooke did such for the Royal Society in 1664.¹ By the early 1800's, Dr. Bozzini, in 1806, performed bladder examination using paper rolled into a tube with a candle behind his ear for illumination.^{2,3} Slowly the endoscopy knowledge and enthusiasm grew along with the development of equipment to examine deeper into these structures.

Bronchoscopy, as developed by early physicians, has had a slow evolution since Hippocrates (460 - 370 BC) first suggested insertion of a pipe into the larynx of a suffocating patient.³ Avicenna used a silver pipe about 1000 AD and Vesalius used a reed in an animal with an open chest to assist respiration.³ Nasotracheal intubation for suffocation and foreign body removal was advised in the 1700's. Tracheotomy and blind tracheal intubation were developing in the mid to late 1800's. Limitations existed, however, that required non-medical scientific

advancement before the patient and the physician might benefit from a more revealing interventional endoscopic view. Better mechanisms were developed to assist in the building of a “scope” and to replace candles or sunlight with a more illuminating light source. In the 1870’s, electricity was discovered by T.A. Edison, and, through research, techniques were developed to safely direct the light through a specific tube toward the target to be examined.

Indirect laryngoscopy (Photograph I), and examination with a laryngeal mirror and the illuminator (a box with a candle) was followed by Edison’s electric bulb. Endoscopy and thoracoscopy then became possible with the use of local anesthesia - especially cocaine.² With the concept of endoscopy now proven, development of techniques to remove foreign bodies or examine specific areas improved and attachment of electric light sources to a hollow metal tube bronchoscope followed. (Photograph II) Gustav Killian developed direct tracheobronchoscopy for foreign body extraction after working on cadavers.⁴ (Photograph III) Early on, Killian also developed the “Killian’s Chair” for the sitting position bronchoscopy.⁴ (Photograph IV) Unfortunately, this chair technique proved cumbersome for some patients and physicians.^{3,4} Meanwhile, the first esophagoscopy was performed by Adolf Kussmaul in 1868 at Strassburg.

Killian used his endoscope for bronchoscopy. In 1897, Killian performed the first translaryngeal bronchoscopic study.³ Shortly after, in the United States, Chevalier Jackson, Karl - Storz, and Pillings all added to the advancement of bronchoscopy. Jackson showed a keen interest in bronchoscopy and further development of the equipment required to perform such.

(Photograph V) By the early 1900’s, many other physicians also became interested in thoracic endoscopy. This included a Swedish internist, Hans C. Jacobaeus, who in 1906 showed an interest in invasive thoracoscopy.⁵ Shortly thereafter, further refinement of the endoscopic techniques and safety design was followed by rigid esophagoscopy.

The extent and quality of the procedures were limited by the available anesthetic - local or general. Cocaine, ether, and procaine became available as these early physicians developed and modified their new endoscopic procedural techniques. The location and available facilities for performance of these procedures were limited as was patient monitoring. Unfortunately, complications and patient discomfort led to shortened and incomplete procedures on many occasions - stimulating further development of safer scopes (Photograph VI).

One of the concerns for these early diagnosticians was the positioning of the patient. Should the patient be supine or in a lateral, prone or upright position. (Photograph VII) Each position had its advantages and risks. Many physicians favored the patient to be supine during bronchoscopy with a registered nurse (R.N.) assistant to hold and maintain the proper head and body position for safe performance of the procedure. Others found the upright or sitting position to be more favorable - the "sword swallowing" technique. We have utilized the rigid bronchoscopic and esophagoscopy techniques in both the sitting and the supine positions on many occasions in many facilities. A case report might illustrate both the rigid technique and an indication for bronchoscopy in the sitting patient.

Case Report

A healthy young, registered female nurse was 7 1/2 months pregnant when seen in emergency consultation by ourselves at 9:00 p.m. one Sunday evening. She related a history of "progressive asthma" treated over the previous 3 years and was now severely dyspneic and markedly cyanotic while sitting upright in a chair. She had an audible stridor while maintaining her chin stretched upwards and forward in order to breathe. Her chest x-ray reportedly showed no abnormality from two years prior. Indeed, it appeared normal on the posteroanterior view. But, on the lateral chest roentgenogram, a "defect" in the tracheal air column was present at the level of the carina. After discussing the findings and options with her, she was immediately

prepared for a tracheobronchoscopy. Local 4% xylocaine was administered percutaneously intratracheally with a #22-gauge needle with the patient sitting upright in a straight back chair. Then, with her neck stretched upward to breathe and her head tilted backward and slightly to the right to lay against my abdomen, she opened her mouth wide. A “4x4” sponge covered her teeth while holding her lips back. Then, with the senior author standing on a low operating room (OR) footstool behind her, a rigid 8 x 40 Jackson bronchoscope was readily inserted. The bronchoscope readily passed between the open vocal cords and almost fell into the straightened trachea. Immediately, a large tumor was visualized nearly totally occluding the tracheobronchial junction at the level of the carina with only a tiny thin moon shaped anterior space in front of the tumor through which air could pass on inspiration. This points out on exam that not all wheezing in an adult is due to asthma.

After multiple telephone consultations with experienced tracheal surgeons from two local and two national medical centers, all of whom declined to accept the patient in transfer, emergency surgery was planned. Six hours later, at 6:00 am the following morning, she was again taken to the operating room and a peroral rigid bronchoscope was passed directly through the tumor in order to ventilate the left lung. Four and one-half minutes later, a healthy female infant was delivered by C-Section. After closure of the uterus and abdominal incision, the patient was positioned on her left side for a right lateral thoracotomy. En bloc resection of the carina and distal trachea along with the tumor was followed by a primary anastomosis of the right and left bronchi to the proximal trachea - forming a new carina. Three decades later, she showed no evidence of recurrence, was breathing well, and both she and her daughter were doing well.⁶

Early History:

The early rigid bronchoscopes had a clear cap or lens through which one could look and yet not have material coughed in the examiner's eyes. The bronchoscopes were straight, rigid, and of various sizes (2 to 8mm) with the light source near the examiner's eye and multiple side port access. (Photograph VIII) As time progressed, a light channel was added so that the illuminating light bulb was placed at the tip end of the scope - near the pathology. This provided much better visualization of both the endo-bronchial regions and the pathology, but with the bulb occasionally covered by mucus or blood. By turning the patient's head from side to side the tip of the scope could then be maneuvered into either the right or the left bronchus. Long rigid telescopes, with various mirror and light angles for better segmental orifice and pathology visualization, were developed to pass through the bronchoscope. Long forceps were devised for tissue biopsy or for removal of foreign bodies. Locally, with the availability of the Jackson bronchoscope and the improved light sources at the distal end of the bronchoscope, bronchoscopy was performed more readily and in special bronchoscopy rooms.

The opportunity to bronchoscope a patient was first presented to the senior author at Cook County hospital - first as a medical student and then as an intern. From that time forward, hundreds of rigid bronchoscopic procedures were performed at multiple facilities with the patient in both the sitting and reclining positions. Table I demonstrates the healthcare locations at which rigid bronchoscopy was performed in the upright sitting position.

Routinely, in each hospital or the university, when it was suggested that we perform the procedure in a sitting position, the staff nurse or OR supervisor would say "no" - you can't do it that way - it can't be done with the patient sitting. In the 1950's to the 1980's, a head holder was always available for positioning the patient's head during rigid bronchoscopy and rigid esophagoscopy. This person was rarely found to be necessary by ourselves when performing bronchoscopy with the patient either in the sitting or lying position. The staff would repeatedly

express concern that it was not possible to perform the procedure without a head holder - whether the patient was sitting up or lying. But, after the procedure, they were always amazed to see its ease of performance during which the mediastinal structures did not compress the airway.

Prior to elective procedures, the patient usually received a light sedative and then gargled a topical anesthetic - either liquid or gel. Frequently, elective patients received preoperative morphine, atropine and nembutal - without any complications. Local intratracheal anesthetic was then injected using an indirect laryngeal mirror for guidance. Initially, 2cc of 10% intratracheal cocaine was utilized as a topical anesthesia. Later 4% xylocaine (2 to 4 cc) was injected percutaneously intratracheally with a #22 needle.

Usually, direct upper lobe segmental visibility was obtained with the rigid bronchoscope while utilizing right angle telescopes. The remainder of the segmental bronchi were visualized directly. When the flexible bronchoscope became available, the number of rigid bronchoscopy procedures and the use of the sitting position for bronchoscopy were reduced. We did continue to perform the occasional upright or semi upright flexible transnasal bronchoscopy in those patients who could not lie down due to severe dyspnea or in those who had marked physical deformities. As with the rigid bronchoscope, few complications were noted while performing the flexible procedure in the sitting position. We further found that certain patients, such as with the above case report, continued to benefit from the sitting or upright position (Table II).

However, there are situations that prohibit the sitting procedure for bronchoscopy. The very apprehensive patient or the medically unstable individual requiring anesthesiology assistance and/or general anesthesia usually contraindicates the upright endoscopy position except as an assistance for endotracheal intubation (Table III). Further, patients with foreign bodies,

especially those objects which are difficult to grasp or very heavy, have required a head down - foot up Trendelenberg position, in order to remove the object with the aid of gravity and the more modern endoscope. Other trans bronchial therapeutic procedures included brachytherapy and bronchial tamponade for bleeding are usually best performed with the patient lying supine.

Literature Review:

Over the years, a number of authors have discussed the performance of bronchoscopy in various positions - including the sitting or upright position.⁷ With the development of the flexible fiberoptic bronchoscope, a rapid utilization conversion from the rigid to the new flexible bronchoscope occurred. As a result of this transition, many newer or more recent endoscopic trainees have never seen nor performed rigid bronchoscopy. But those with the rigid bronchoscopy experience almost certainly have never seen the procedure performed under local anesthesia with the patient sitting upright in a chair.

Fifty years ago, the only bronchoscopes were rigid in construction and the light source was less than dependable - frequently burning out during the procedure. The light carrier would then be replaced, or a new bulb placed. In addition, the bronchoscopes of that era had a lens near your eye for visualization but a long distance from the area of potential pathology to the eye, while placing the physician's eye in a direct line with the coughed or expectorated material. Hence, a protective "welders" wrap around head shield, a rotating clear plastic disk, or glasses were worn by the endoscopist between the bronchoscope and the bronchologist - a valuable protective eye device. This aided in the prevention of infectious agents - such as tuberculosis - or of tumor cells being coughed in the face or eye of the endoscopist or, when present, the head holder.

Most endoscopists utilized a "head holder" for stabilization of the patient's hyperextended head during a supine rigid procedure. This was not a requirement for the senior author during a sitting (as presented) or a supine bronchoscopic procedure during which he would sit on a stool

and rest the patient's head on his knee and manipulate the OR table and headrest as necessary. When performing bronchoscopy with the patient sitting in a chair or in the upright position in an intensive care unit (ICU) bed, one would stand behind the patient with the neck hyperextended and the head slightly turned to the right. The rigid endoscope (usually an 8 x 40 in the adult) would almost fall between the cords into the trachea. The patients were able to breathe more readily with the delivery of oxygen through a side port on the bronchoscope and usually were very "comfortable." Many required little or no anesthesia - topical or intravenous. (Photograph IX)

Bronchoscopic techniques have advanced rapidly with most procedures now performed in the supine position utilizing a flexible bronchoscope. There does still remain an occasional need to perform the endoscopic procedure in the upright position. This has been highlighted in a number of circumstances such as the patient with a large or enlarging neck mass - especially when the patient requires tracheal intubation.⁸ Diagnosis of and treatment for children's upper airway obstruction has also utilized the sitting position for the acutely dyspneic child.⁹ Other physicians, however, have felt that a supine position with low flow supplemental oxygen was preferable.¹⁰

Kedla, et al evaluated the use of the flexible bronchoscope in upright patients with coexistent airway disease and poor lung function.¹¹ They, and others, concluded that bronchoscopy was an acceptable safe procedure performed in the upright and sitting position in these pulmonary limited patients.⁹ We have also found that diagnosis or treatment of patients in the sitting position may be safely accomplished utilizing either the rigid or flexible scope. Carcinomas may be diagnosed, and tracheal or bronchial stenosis located and dilated. Routine analgesia and possible sedation have been utilized before, during, and after the procedure. But, in the severely dyspneic, cyanotic, and unstable adult situation with severe post long term

endotracheal tube induced tracheal stenosis (2 - 3 mm orifice) the patients were preferentially dilated under general anesthesia while supine through progressive rigid bronchoscopic dilation utilizing progressively larger bronchoscopic sizes.

On occasion, the only anesthetic utilized was the topical agents. Using this policy, some physicians have preferred the supine over the upright position in the pneumocystis carinii (PCP) suspect.¹² However, the awake patient on a respirator with an endotracheal tube in place may be more comfortable in the sitting or semi upright position during endoscopy. These patients may thus tolerate bronchoscopy better in the upright or semi-erect position. As previously mentioned, the individual patient in whom little or no sedation and little or no anesthesia will be utilized has accepted and tolerated the upright or nearly upright sitting position rigid or flexible bronchoscopy - some on a daily basis when in the intensive care unit for a week or more.

Table I

Facilities Where Sitting Rigid Bronchoscopy Was Performed
by the Senior Author (Raymond A. Dieter, Jr., M.D.)

Year	Place	Position	City
1960 - 1961	Cook County Hospital	Student/Intern	Chicago, Illinois
1961 - 1963	USPHS Hospital	Lieutenant	Mt. Edgecumbe, Alaska
1965 - 1966	Hines Veterans Hospital	General Surgery Resident	Hines, Illinois
1967 - 1969	Hines Veterans Hospital	Thoracic Resident	Hines, Illinois
1969 - 1979	Loyola University	Attending	Maywood, Illinois
1970 - 1985	Central DuPage Hospital	Attending	Winfield, Illinois
1972 - 1985	Elmhurst Hospital	Attending	Elmhurst, Illinois

Table II

Possible Indications for Upright or Sitting Bronchoscopy

- I. Severe Dyspnea lying down
- II. Large tumor masses in neck (ex. a huge tracheal compressing thyroid)
- III. Pediatrics - to discern acute, upper airway obstruction
- IV. Patient apprehension when lying down
- V. Assist in endotracheal intubation
- VI. Postoperative intensive care patients in an ICU bed

Table III

Situations Which May Prohibit The Sitting Bronchoscopy

- I. Patient medically unstable
- II. Extreme apprehension
- III. Concern for bleeding
- IV. Need for upper lobe biopsy
- V. Mobile foreign bodies (especially heavy) (We have found the head down supine position may be best.)

Reference

1. Moore, W. The knife man. Broadway Books. New York. 2005:7
2. Bozzini P.: Lichleiter, eine Erfindung zur Anschauung innerer Theile und Krankheiten. Neues Journal der Practischen Arzneykunde und Wundarzneykunst (Berlin) 1806;24:107-124.
3. Becker, HD. History of the rigid bronchoscope. Principles and practice of interventional pulmonology. Springer Science and Business Media. A. Ernst and F. J. F. Heath (Eds). New York. 2013. (Ch 1) 3- 13
4. Nicastrì DG and Weiser TS. Rigid bronchoscopy: indications and techniques. Operative Tech in Thor Cardiovasc Surg (Elsevier, Inc) 2012: 44 - 51
5. Dieter, RS. The history of thoracoscopy. Thoracoscopy for surgeons - diagnostic and therapeutic. Igaku - Shoin, Dieter Jr RA. New York. 1995: Ch 1; 1 - 13
6. Dieter Jr RA, Livermore J, Tu R, Picchietti J. Mucoepidermoid tracheal adenoma during pregnancy: A case report. Int'l Surg. 1983(3);68:271-272
7. Brown RK, Kovarik JL. Bronchoscopy in the sitting position. Surg Cl N Amer. 1969 Dec;49(6):1421-4
8. Dabbagh A, Mobasserì N, Elyasi H, Gharaehi B, Fathololomi M, Ghasemi M, Chamkhale IB. A rapidly enlarging neck mass: The role of the sitting position in fiberoptic bronchoscopy for difficult intubation. Anesth and Analg. 2008 Nov;107 (5):1627-9
9. Vauthy PA and Reddy R. Acute upper airway obstruction in infants and children. Evaluation by the fiberoptic bronchoscope. Ann Otol, Rhinol, Laryngol. 1980 Sept - Oct;89 (5 Pt 1):417-8
10. vanZwam JP, Kapteijns EF, Lahey S, Smit HJ. Flexible bronchoscopy in supine or sitting position: a randomized prospective analysis of safety and patient comfort. J Bronch and Intervent Pulm. 2010 Jan;17(1)29-32

11. Kedla R, Olivelra S, Broman D. Is bronchoscopy in the upright position, a safe procedure in patients with coexistent airways disease and poor lung function. *Am J Respir Cit Care Med* 2011;183:A2349
12. Vijayanand P, Woodhead M. Bronchoscopy in patients with suspected PCP: supine or sitting? *Thorax*. 2003 Aug;58(8):736.

Photographs

- I. Indirect laryngoscopy (Courtesy Heinrich D. Becker)
- II. Lower tracheoscopy anterior approach 1896 (Pieniazik) while sitting (Courtesy Heinrich D. Becker)
- III. Killian developing tracheoscopy and laryngoscopy techniques on frozen corpse for upper airway exam (Courtesy Heinrich D. Becker)
- IV. Killian sitting chair position for bronchoscopy procedure (Courtesy Heinrich D. Becker)
- V. Jackson traveling case showing various bronchoscopic equipment (Courtesy Heinrich D. Becker)
- VI. Double scope (one within the other) with a spring to prevent intratracheal scope loss due to slippage (Courtesy Heinrich D. Becker)
- VII. Rigid bronchoscope performed in various live patient positions (Courtesy Heinrich D. Becker)
- VIII. Rigid broncoscope with multiple access ports (Courtesy Heinrich D. Becker)
- IX. Rigid and flexible bronchoscope (Courtesy Heinrich D. Becker)

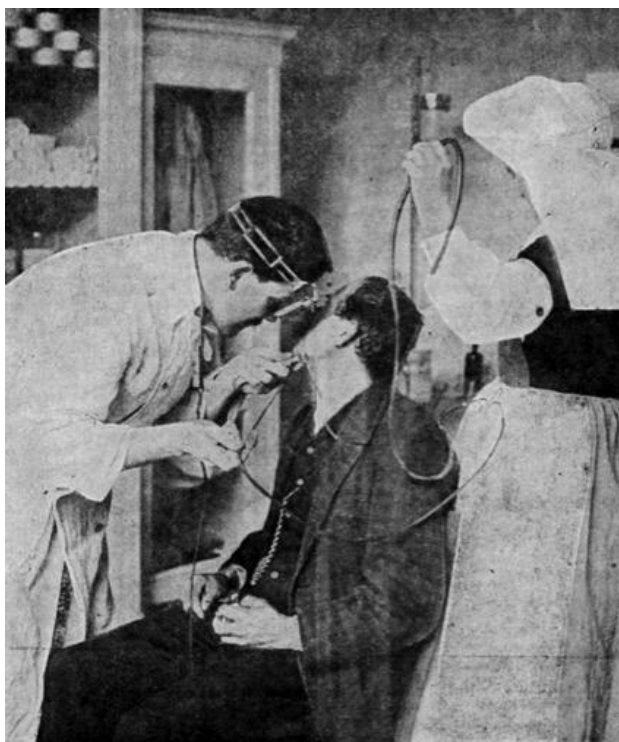Photograph I
Indirect Laryngoscopy
(Courtesy Heinrich D. Becker)



Photograph II

Lower Tracheoscopy Anterior Approach 1896 (Piencazik) While Sitting

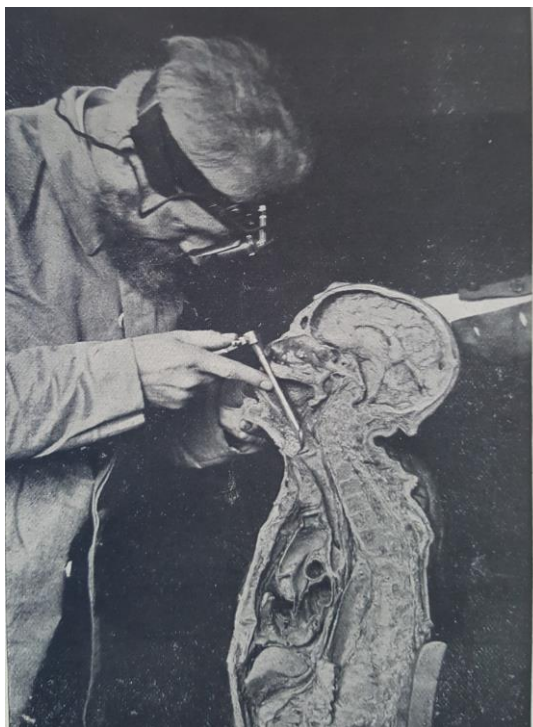
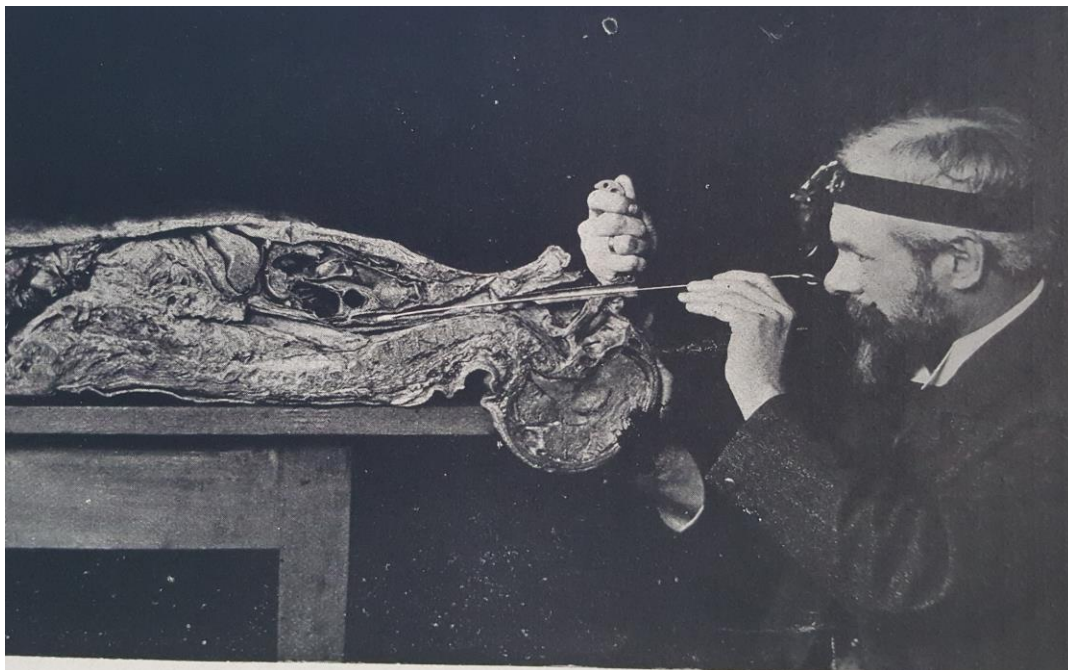(Courtesy Heinrich D. Becker)



Photograph III

Killian Developing Tracheoscopy and Laryngoscopy Techniques of Frozen Corpse for Upper
Airway Exam

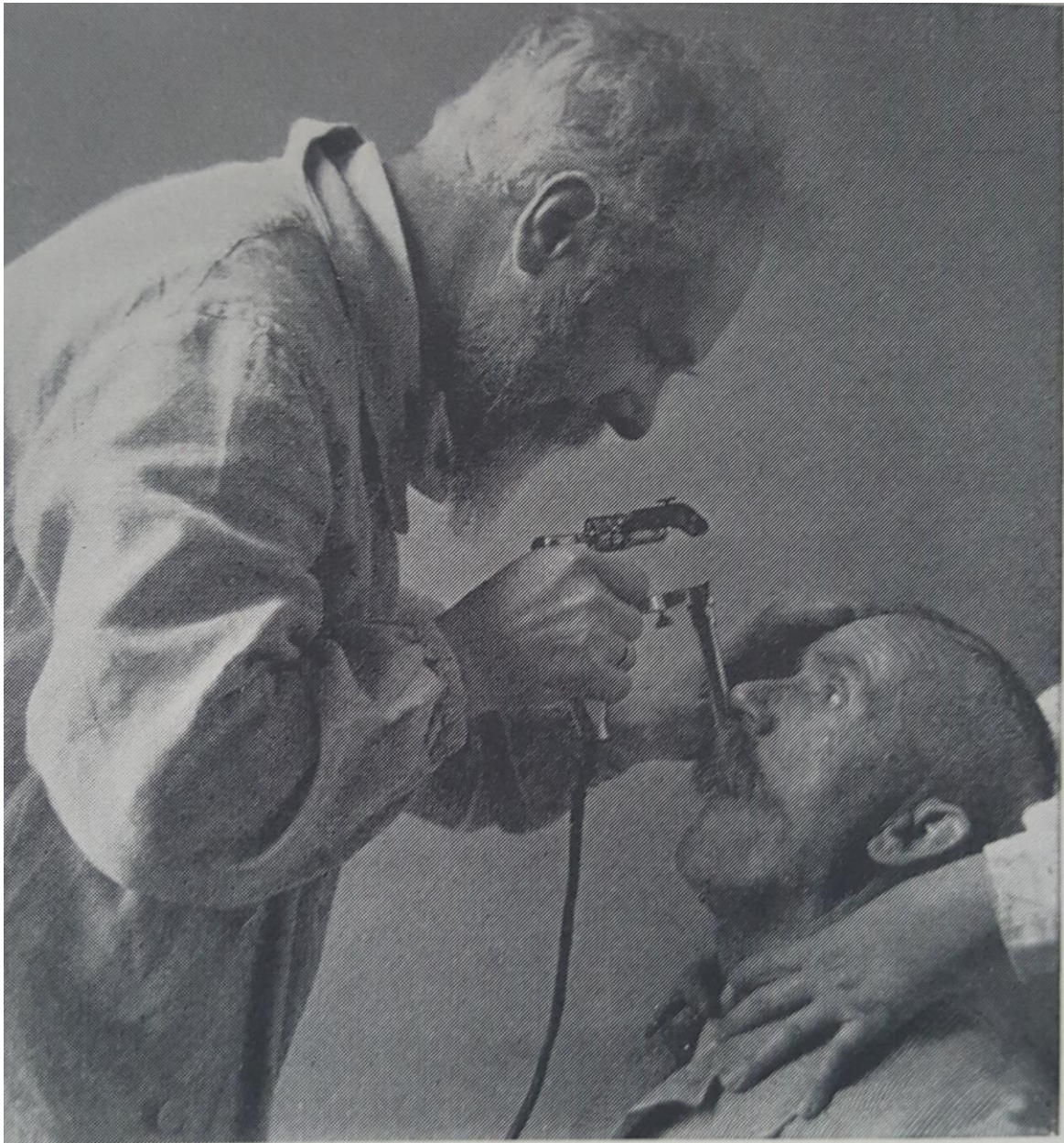
(Courtesy Heinrich D. Becker)



Photograph IV

Killian Sitting Chair Position During Bronchoscopy Procedure

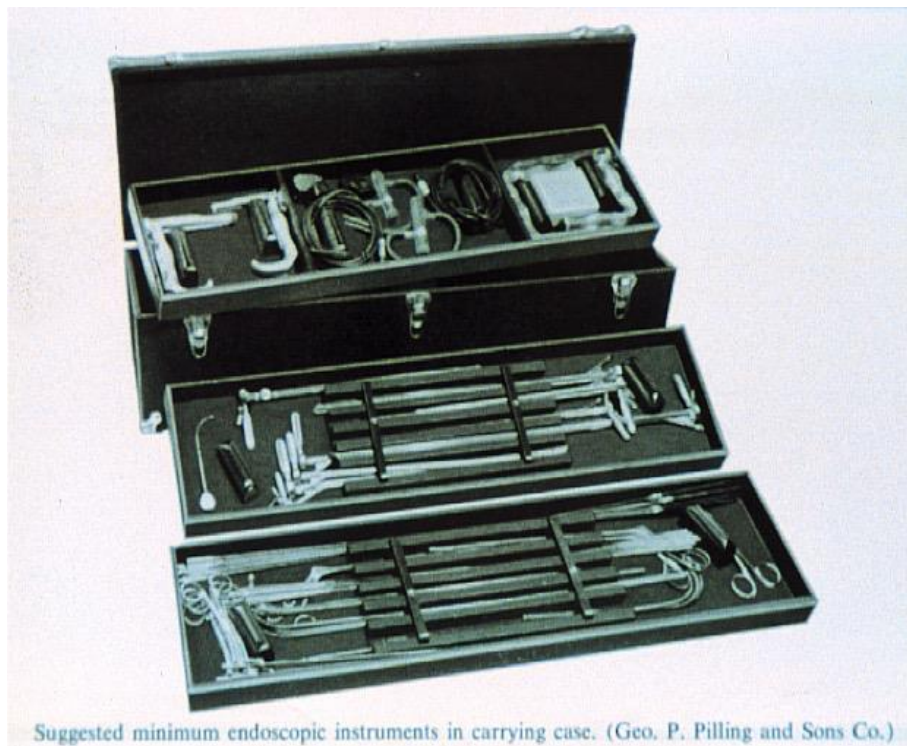(Courtesy Heinrich D. Becker)



Photograph V

Jackson Traveling Case Showing Various Bronchoscopic Equipment Items

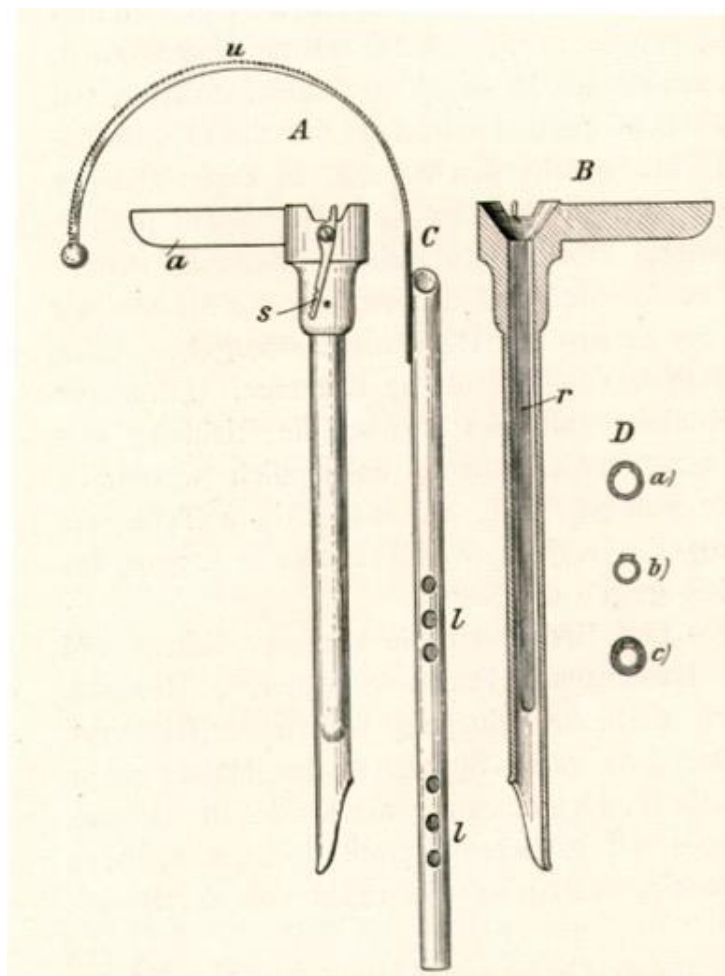
(Courtesy Heinrich D. Becker)



Photograph VI

Double Scope with Spring to Prevent Intratracheal Loss Due to Slippage

(Courtesy Heinrich D. Becker)



Photograph VII

Rigid Bronchoscope Performed in Various Live Patient Positions

(Courtesy Heinrich D. Becker)



Abb. 335. Untersuchung in Bauchlage.

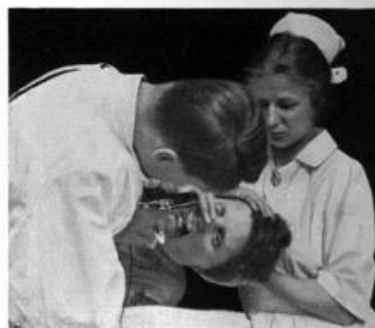

Abb. 336. Untersuchung in linker Seitenlage.

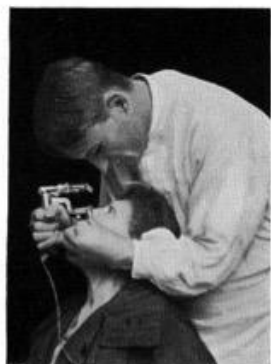

Abb. 337. Untersucher steht hinter der sitzenden Patientin.

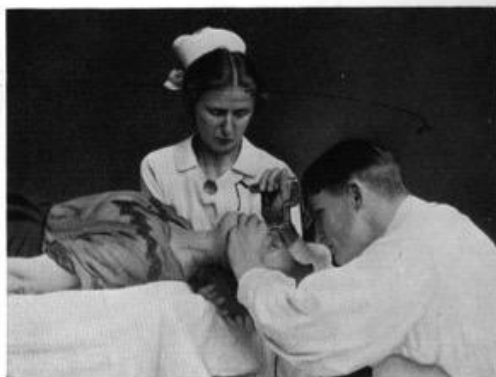

Abb. 338. Untersuchung in Rückenlage.

Photograph VIII

Rigid Bronchoscope with Multiple Access Ports by J.F. Dumon

(Courtesy Henrich D. Becker)



Photograph IX

Rigid and Flexible Bronchoscope

(Courtesy Henrich D. Becker)

