



Case Report

Ileosigmoid Knot at Week 13 of Pregnancy: Report of a Case

Riha Shimizu¹, Yoshinori Hoshino¹, Haruko Irie², Homare Ito¹, Toshiaki Terauchi¹, Masaru Kimata¹, Junji Furukawa¹, Hiroharu Shinozaki¹, Kenji Kobayashi¹, Yoshiro Ogata¹

¹Department of Surgery and ²Department of Obstetrics and Gynecology, Saiseikai Utsunomiya Hospital, Tochigi, Japan

The ileosigmoid knot (ISK) is a rare cause of intestinal obstruction. ISK is a condition in which the ileum wraps around the base of the sigmoid colon and forms a knot, leading to high mortality with rapid progression to bowel gangrene. We herein report a rare case of ISK at week 13 of pregnancy. The ISK was diagnosed by computed tomography, and the patient underwent emergency surgery for acute abdomen. Laparotomy showed segmental gangrenous change in the sigmoid colon, which was twisted around the distal ileal loop. The gangrenous bowel was resected, and primary anastomosis was performed. To our knowledge, the present case involves the first and earliest pregnancy in which a preoperative diagnosis of ISK was made and successful treatment was performed with surgery. A radiologic approach should be undertaken for prompt diagnosis and optimal management, even in early pregnancy.

Key words: Ileosigmoid knot – Pregnancy – Emergency surgery – Strangulation – Small bowel obstruction

The ileosigmoid knot (ISK) is a rare cause of intestinal obstruction. ISK is characterized by wrapping of the ileum around the base of the sigmoid colon, forming a mechanical bowel obstruction with rapid progression to bowel gangrene. ISK is associated with 0.5% to 1.7% of intestinal obstructions, and the reported mortality rate varies from 0%

to 48% (mean, 35.5%).^{1–3} The mortality rate of ISK with bowel gangrene is reportedly as high as 20% to 100%.³ Because the knot involving the ileum and sigmoid colon can be difficult to untie, this condition usually requires laparotomy. We experienced a rare case of ISK in a patient in early pregnancy who underwent emergency surgery for acute abdomen.

Corresponding author: Yoshinori Hoshino, MD, Department of Surgery, Saiseikai Utsunomiya Hospital, 911-1 Takebayashi, Utsunomiya, Tochigi 321-0974, Japan.

Tel.: +81-28-626-5500; Fax: +81-28-626-5594; E-mail: ymailbiz@gmail.com

Case Report

A 28-year-old woman in the 13th week of pregnancy was referred to the emergency department of our hospital for sudden abdominal pain. She had neither a medical nor surgical history and had thus far experienced a normal pregnancy. Upon arrival, her blood pressure was 114/56 mmHg, pulse rate was 96/min, and body temperature was 35.8°C. Physical examination revealed abdominal distension and left lower abdominal tenderness. Laboratory data showed a white blood cell count of 15,100/mm³, hemoglobin level of 13.4 g/dL, and C-reactive protein level of 0.3 mg/dL (normal, <0.3 mg/dL). Transvaginal ultrasonography (US) revealed a dilated bowel without ascitic fluid and no abnormal findings in her infant. She was admitted to our hospital for intensive observation and because of the possibility of miscarriage or enteritis. Transabdominal US was performed after admission because of rapidly worsening abdominal pain with diffuse and rebound tenderness. An X-ray of the abdomen showed dilatation of the small intestine with air-fluid levels and the presence of a sigmoid colon loop in the mid-abdomen (Fig. 1). Enhanced abdominal computed tomography (CT) was performed to reach an accurate diagnosis after obtaining detailed informed consent regarding the risk of radiation exposure. The CT scan revealed 2 abnormal findings: (1) whirling of the sigmoid mesocolon and mesenteric root, suggestive of strangulation, and (2) a dilated loop of the sigmoid colon in the right lower abdomen, suggestive of a sigmoid volvulus (Figs. 2a–2c). She was diagnosed with strangulation caused by ISK. She underwent emergency exploratory laparotomy, and 2 L hemorrhagic ascitic fluid with gangrenous change in the ileum and sigmoid colon was identified (Fig. 3a). The ileum was twisted 720° clockwise around the sigmoid colon (Fig. 3b). The gangrenous ileum and sigmoid colon were treated by resection with primary anastomosis, respectively. She was discharged with no complications 14 days after surgery. She delivered at term, and her baby had neither physical nor mental impairment.

Discussion

ISK is a rare form of bowel obstruction in which the ileum wraps around the base of the sigmoid colon. ISK is predominately seen in male patients (80.2%) with mean age of 40 years (range, 4–90 years).^{1,2} Several studies have reported the relationship

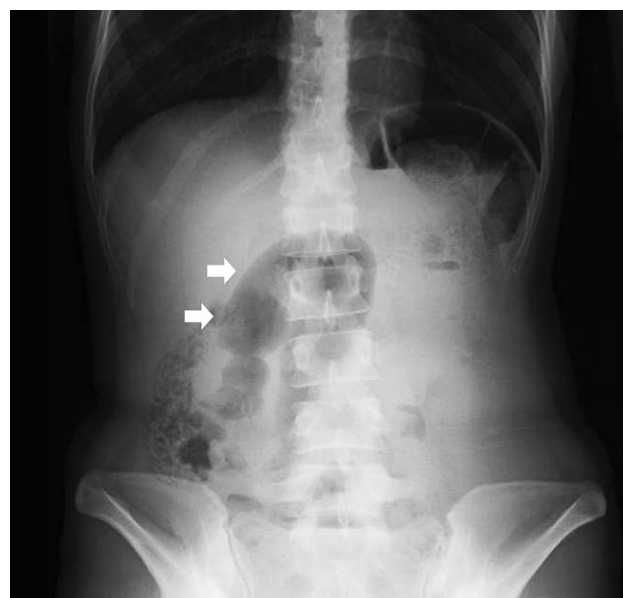

Fig. 1 An abdominal X-ray reveals a sigmoid colon loop (white arrows) in the mid-abdomen.

between dietary habits and ISK in that ingestion of a single daily meal was associated with a higher incidence of ISK.^{1,3,4} This gives insight into the mechanism of ISK. When a semiliquid, bulky meal progresses into the proximal jejunum, it increases the mobility of the intestine. The heavier segments of the proximal jejunum then fall into the left lower quadrant. The empty loops of the ileum and distal jejunum twist and rotate around the base of the narrow sigmoid colon.⁴ Subsequent peristalsis results in the formation of an ISK with an obstruction involving 2 closed loops: one in the small intestine and the other in the sigmoid colon.

Anatomic factors are also known to be responsible for ISK, including a long small bowel mesentery and freely mobile small bowel, and a long sigmoid colon on a narrow pedicle.^{1,5} A predisposing risk factor for ISK is late pregnancy because of the obvious displacement of the bowel. In the present case, the patient was in early pregnancy; thus, formation of the ISK in this case was not related to displacement of the bowel resulting from an enlarged uterus. One possible risk factor for ISK in the present case was an unbalanced oral intake owing to morning sickness during the pregnancy, together with the anatomic bowel features mentioned above.

Twelve cases of ISK in the perinatal period were identified in PubMed using the keywords “ileosigmoid knot, ileal knotting” and “pregnancy, labor”

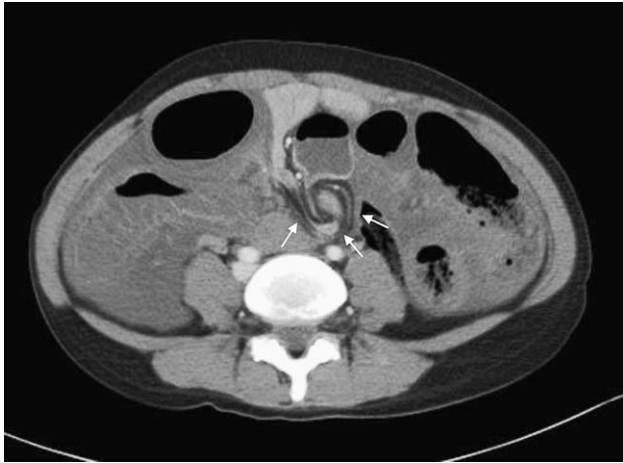


Fig. 2 (a) Contrast-enhanced CT scan (axial view) shows a dilated loop of intestine with a surrounding whirl (small white arrows).

(Table 1).⁵⁻⁹ The present case involved the earliest pregnancy of all reported cases. Moreover, ISK was not diagnosed preoperatively in any case other than the present case. The accuracy of preoperative diagnosis of ISK is generally reported to be as low as 0% to 28% because of its infrequency and atypical radiographic findings.^{3,7,10,11}

The gold standard radiographic imaging modality for the evaluation of acute abdomen, including ISK, is CT with high spatial resolution. The safety of radiation exposure during pregnancy is a common

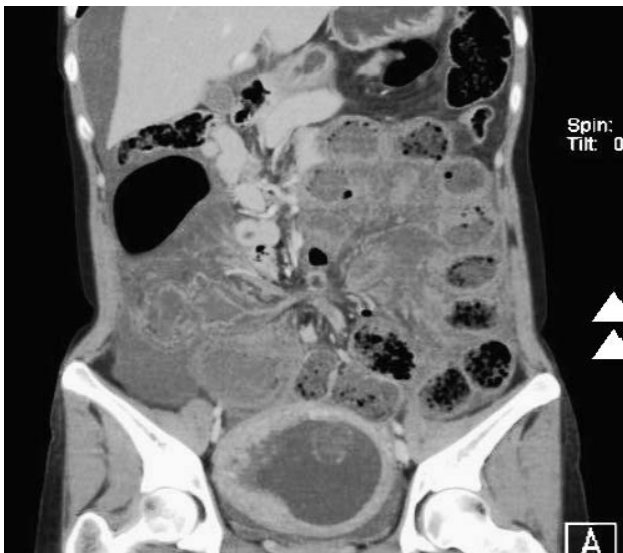

Fig. 2 (b) Contrast-enhanced CT scan (coronal view) shows distended sigmoid colon (white arrowhead).

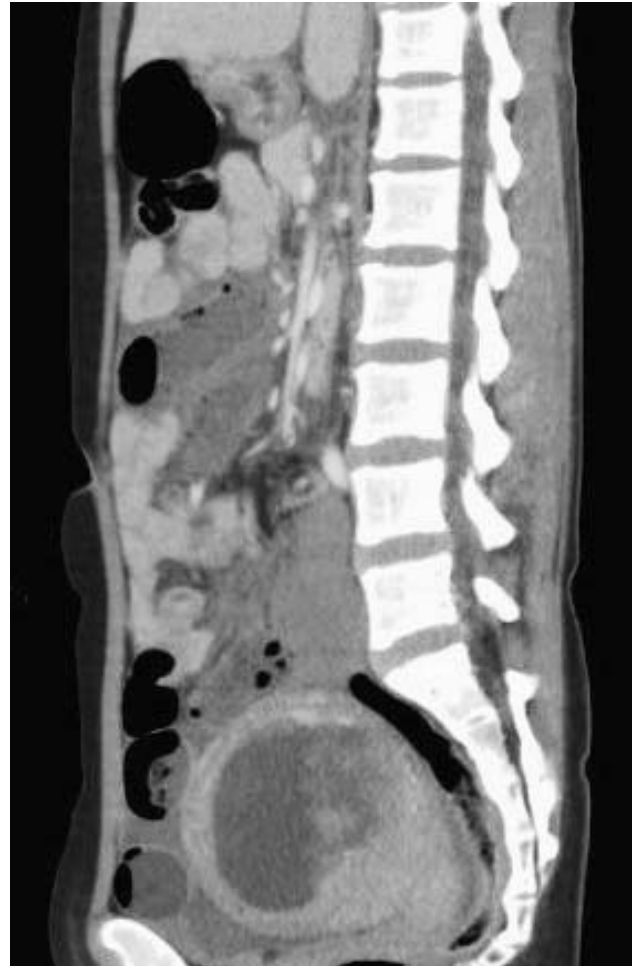

Fig. 2 (c) Contrast-enhanced CT scan (sagittal view).

concern. Radiation exposure to pregnant women undergoing medical imaging procedures and the management of such patients are difficult topics to address. There are radiation-related risks throughout pregnancy, and these risks are associated with the stage of pregnancy and absorbed dose. To diminish these prenatal risks, the radiation dose should be minimized. The first-line examination of a pregnant woman with abdominal pain should be US, which is free from radiation exposure, less expensive, and comparatively safer than CT. However, the skill level of the operator greatly influences the results. Moreover, Lazarus *et al*¹² found that CT findings provided important diagnostic information in 30% of pregnant women with abdominal pain who were determined to have normal US findings. On the other hand, the efficacy of magnetic resonance imaging (MRI) has been reported for the diagnosis of acute abdomen in adults.¹³ There are no

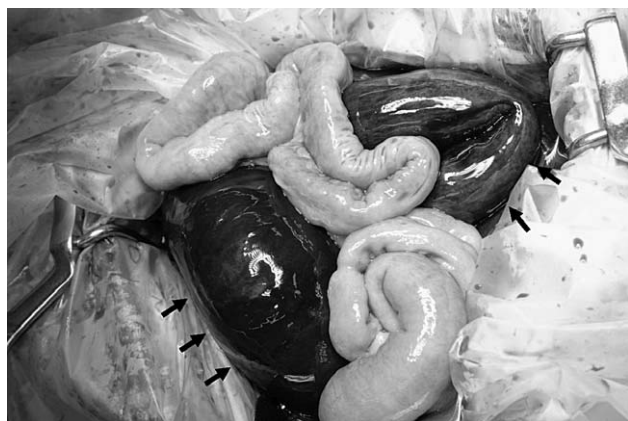

Fig. 3 (a) Intraoperative photograph shows gangrenous change in the ileum and sigmoid colon (black arrows).

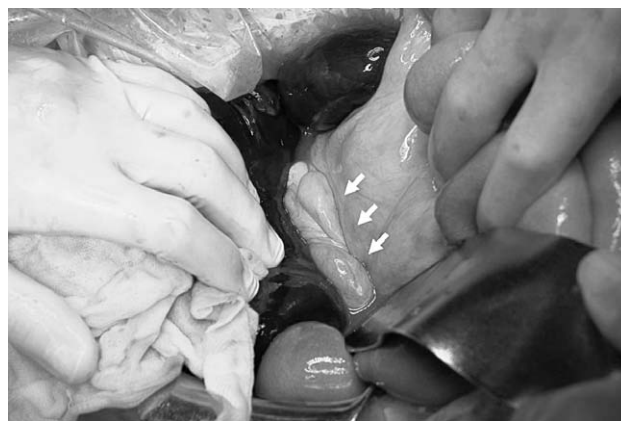

Fig. 3 (b) Ileosigmoid knot (white arrows) with gangrenous ileum and sigmoid colon.

reported harmful effects of MRI on the pregnant woman or fetus. However, the National Radiological Protection Board in the United Kingdom advises that MRI be avoided in the first trimester because there is limited experience assessing its safety during organogenesis. MRI for acute abdomen in pregnancy should be further evaluated in clinical studies.

According to the International Commission on Radiological Protection, radiation risks are most significant during organogenesis and in the early

fetal period, less in the second trimester, and least in the third trimester.¹⁴ Malformations have a threshold of 100 to 200 mGy or higher and are typically associated with central nervous system problems.¹⁴ However, 3 pelvic CT scans or 20 conventional diagnostic X-ray examinations do not reach the fetal threshold of 100 mGy.¹⁴ Therefore, prenatal doses of most properly performed procedures for the diagnosis of acute abdomen present no measurably increased risk of prenatal death, malformation, or mental impairment. Efforts to avoid radiation

Table 1 Summary of data of patients with ileosigmoid knot during pregnancy

Patient No.	Age, y	Pregnancy, wk	Preoperative diagnosis of ISK	Bowel involvement	Operation	Mortality/morbidity	Reference
1	31	16	Negative	Sigmoid colon	Primary sigmoid resection	None	Atamanalp <i>et al</i> ⁸
2	35	27	Negative	Ileum/ sigmoid colon	Ileum and sigmoid resection, ileal anastomosis	Abortion	Atamanalp <i>et al</i> ⁸
3	38	27	Negative	Ileum/ sigmoid colon	Ileum and sigmoid resection, ileal anastomosis	Died of sepsis	Atamanalp <i>et al</i> ⁸
4	28	1 Day after delivery	Negative	Ileum	Ileal resection	Died of abdominal compartment syndrome	Ucar <i>et al</i> ⁶
5	30	N/A	Negative	Ileum/ sigmoid colon	Ileum and sigmoid resection, ileal anastomosis	Died of sepsis during operation	Vaez-Zadeh <i>et al</i> ⁹
6	18	N/A	Negative	Ileum/ sigmoid colon	Ileum and sigmoid resection, ileal anastomosis	Died of abdominal wound dehiscence	Vaez-Kadeh <i>et al</i> ⁹
7	28	13	Positive	Ileum/ sigmoid colon	Ileum and sigmoid resection, ileal anastomosis	None	Present case

N/A, not applicable.

exposure in women with acute abdomen during pregnancy may lead to a diagnostic delay, especially in early pregnancy. A missed or delayed diagnosis can pose a greater risk to the woman and fetus than any hazard associated with ionizing radiation. Radiation exposure may be responsible for the difficulty in obtaining an accurate diagnosis of ISK in the perinatal period, which may explain the high mortality and morbidity rates in previous reports (Table 1). In the present case, enhanced abdominal CT was performed for evaluation of acute abdomen in early pregnancy, and an emergency laparotomy saved both the mother and child. This is the first case in which an ISK during pregnancy was preoperatively diagnosed and successfully treated with surgery.

In conclusion, CT should be performed for a prompt diagnosis and optimal management of acute abdomen, including ISK and even in early pregnancy.

References

1. Machado NO. Ileosigmoid knot: a case report and literature review of 280 cases. *Ann Saudi Med* 2009;**29**(5):402–496
2. Shepherd JJ. Ninety-two cases of ileosigmoid knotting in Uganda. *Br J Surg* 1967;**54**(6):561–566
3. Mandal A, Chandel V, Baig S. Ileosigmoid knot. *Indian J Surg* 2012;**74**(2):136–142
4. VerSteeg KR, Whitehead WA. Ileosigmoid knot. *Arch Surg* 1980;**115**(6):761–763
5. Atamanalp SS. Ileosigmoid knotting in pregnancy. *Turk J Med Sci* 2012;**42**(4):553–558
6. Ucar NS, Yuksel BC, Hengirmen S. Did ileal knotting trigger labor or did labor cause ileal knotting? Report of a case. *Surg Today* 2009;**39**(5):440–443
7. Alver O, Oren D, Tireli M, Kayabaşı B, Akdemis D. Ileosigmoid knotting in Turkey: review of 68 cases. *Dis Colon Rectum* 1993;**36**(12):1139–1147
8. Atamanalp SS, Oren D, Başoğlu M, Yildirgan MI, Balik AA, Polat KY *et al.* Ileosigmoid knotting: outcome in 63 patients. *Dis Colon Rectum* 2004;**47**(6):906–910
9. Vaez-Zadeh K, Dutz W. Ileosigmoid knotting. *Ann Surg* 1970;**172**(6):1027–1033
10. Lee SH, Park YH, Won YS. The ileosigmoid knot: CT findings. *AJR Am J Roentgenol* 2000;**174**(3):685–687
11. Puthu D, Rajan N, Gokuldas MS, Pai SU. The ileosigmoid knot. *Dis Colon Rectum* 1991;**34**(2):161–166
12. Lazarus E, Mayo-Smith WW, Mainiero MB, Spencer PK. CT in the evaluation of nontraumatic abdominal pain in pregnant women. *Radiology* 2007;**244**(3):784–790
13. Birchard KR, Brown MA, Hyslop WB, Firat Z, Semelka RC. MRI of acute abdominal and pelvic pain in pregnant patients. *AJR Am J Roentgenol* 2005;**184**(2):452–458
14. Brent R, Mettler F, Wagner L, Streffer C, Berry M, Kusama T *et al.* International Commission on Radiological Protection, 2000: pregnancy and medical radiation. ICRP Publication 84. *Ann ICRP* 2000;**30**(1):1–43.

© 2014 Shimizu et al.; licensee The International College of Surgeons. This is an Open Access article distributed under the terms of the Creative Commons Attribution Non-commercial License which permits use, distribution, and reproduction in any medium, provided the original work is properly cited, the use is non-commercial and is otherwise in compliance with the license. See: <http://creativecommons.org/licenses/by-nc/3.0>