

The Role of 3-D Endorectal Ultrasound in Rectal Cancer: Our Experience

Nikola Y. Kolev¹, Anton Y. Tonev¹, Valentin L. Ignatov¹, Aleksander K. Zlatarov¹, Vasil M. Bojkov¹, Tanya D. Kirilova², Elitsa Encheva³, Krasimir Ivanov¹

¹Clinic of surgery,

²Division of gastroenterology,

³Radiotherapy Department, St. Marina University Hospital, Medical University of Varna, Varna, Bulgaria

In the last 20 years, endorectal ultrasound (ERUS) has been one of the main diagnostic methods for locoregional staging of rectal cancer. ERUS is accurate modality for evaluating local invasion of rectal carcinoma into the rectal wall layers (T category). Adding the three-dimensional modality (3-D) increases the capabilities of this diagnostic tool in rectal cancer patients. We review the literature and report our experience in preoperative 3-D ERUS in rectal cancer staging. In the group of 71 patients, the staging of preoperative 3-D endorectal ultrasonography was compared with the postoperative morphologic examination. Three-dimensional ERUS preoperative staging was confirmed with morphologic evaluation in 66 out of 71 cases (92.9%). The detection sensitivities of rectal cancer with 3-D ERUS were as follows: T1, 92.8%; T2, 93.1%; T3, 91.6%; and T4, 100.0%; with specificity values of T1, 98.2%; T2, 95.4%; T3, 97.8%; and T4, 98.5%. Three-dimensional ERUS correctly categorized patients with T1, 97.1%; T2, 94.3%; T3, 95.7%; and T4, 98.5%. The percentage of total overstaged cases was 2.75% and that of understaged cases was 6.87%. The metastatic status of the lymph nodes was determined with a sensitivity of 79.1% (19 of 24), specificity of 91.4% (43 of 47), and diagnostic accuracy of 87.3% (62 of 71). In our experience, 3-D ERUS has the potential to become the diagnostic modality of choice for the preoperative staging of rectal cancer.

Key words: Three-dimensional endorectal ultrasound – Rectal cancer

Corresponding author: Anton Tonev, MD, PhD, Clinic of Surgery, University Hospital St. Marina, 1 Hr. Smirnenski Boulevard, 9000 Varna, Bulgaria.

Tel.: +359 885 100621; E-mail: teraton@abv.bg

Endorectal ultrasound (ERUS) has been used as a diagnostic tool for evaluation and staging of rectal cancer since the 1980s.¹ According to the literature, in studies with more than 50 patients included, an overall accuracy of approximately 81.8% was reported.² Most of the studies present data between 85% and 95%, but in the studies with more than 200 patients, the accuracy rates are relatively lower—63.3% and 69%, respectively.^{3,4} A common disadvantage of ERUS and magnetic resonance imaging (MRI) is the overstaging of T2 tumors owing to an irregular outer rectal wall resulting from transmural tumor extension or inflammation around the tumor. Another challenge for the ERUS, and especially the rigid probes, are the locally advanced, stenotic tumors, where the probe may not be able to pass above the lesion.⁵ The nodal staging accuracy of ERUS ranges from 70% to 75%.^{1,5,6} The metastatic lymph nodes are distinguished by hypoechoic appearance, round shape, peritumoral location, and size >5 mm.^{7,8} Lymph nodes >5 mm have a 50% to 70% chance of being malignant, while those <4 mm have only a 20% chance.^{9,10} A new modality of endorectal ultrasound represents a three-dimensional (3-D) ERUS that provides better visual images of the tumor volume and spatial relations to the adjacent organs and structures, even better than those of MRI, which leads to better diagnostic accuracy than MRI and standard ERUS.^{11–15} The unique 3-D-ERUS longitudinal scan can precisely assess the tumor size and location.¹⁶ The most important feature of this upgraded modality is the ability to reduce interpreter errors and offer potential predictive value. Three-dimensional ERUS provides the possibility to distinguish blood vessels from lymph nodes and allow precise fine needle aspiration (FNA) biopsies.^{13,17} The infiltration of circumferential margin has been proven to correlate with T category, lymph node metastasis histologic tumor differentiation, and lymphovascular invasion.^{13,17} Three-dimensional ERUS gives the possibility of multiplane evaluation of the tumor, allowing visualization of more subtle changes in the tumor characteristics and therefore better T and N categorizing.¹⁸ A review of 86 patients who underwent standard 3-D ERUS, ERUS and 4-channel detector computed tomography (CT) demonstrated T-category accuracy of 78%, 69%, and 57%, respectively.¹⁹ After analysis of the examiner's error, the accuracy of 3-D ERUS for T category has reached 91% for 3-D ERUS and 88% for standard ERUS, and the N category accuracy improved to 90% and 76%, respectively. Also, ERUS

can be used for diagnosis of premalignant lesions such as adenomas and polyps.²⁰ The main goal is to properly identify any chance of tumor invasion in the primary lesion and involvement of the surrounding lymph nodes in case the absence of those alarming characteristics allows for endoscopic resection of the lesion. Using higher-resolution probes, ERUS can distinguish T0 from T1 lesions. According to a meta-analysis of 258 biopsy-negative tumors, ERUS identified tumor mass in 81% of the 24 lesions, which were found to be invasive tumors on morphologic examination.²⁰ Another series of 60 patients with pT0/pT1 lesions demonstrated sensitivity and specificity of ERUS 89% and 88%, respectively.²¹ As with MRI, 3-D ERUS could provide an evaluation of the mesorectal fascia.^{14,22}

The reported data lead to the position that 3-D ERUS combines the high-resolution images of the rectal wall and cost-effectiveness of standard ERUS with the multiplanar and stereoscopic imaging capabilities of MRI. Three-dimensional ERUS may be the future premier imaging modality used in rectal cancer management.

Methods

Between September 2008 and December 2010, 71 consecutive subjects with rectal cancer were admitted to Clinic of Surgery, University Hospital (St. Marina), Varna, Bulgaria. All subjects underwent 3-D ERUS after verification of rectal adenocarcinoma. The patients underwent bowel preparation with laxative (hydroxyanthracene glycosides, X-prep; Mundipharma GmbH, Limburg, Germany) and 3 enemas—2 the night before and 1 the day of the examination. All patients had sigmoidoscopy prior to the ERUS for verification of good level of cleansing. In 2 patients, the results from sigmoidoscopy showed an unsatisfactory level of cleansing, and the procedure of bowel preparation was repeated. In those cases, the 3-D ERUS was scheduled for the next day. Postoperative pathologic examinations were carried out in all subjects. There were 41 men and 30 women (mean age, 61.3 ± 12.2 years; range, 39–78 years). Inclusion criterion was primary rectal cancer. Exclusion criteria included multiple primary colon cancer, synchronous or metachronous second primary malignancy, intracorporeal metal parts, severe claustrophobia, and pregnancy.

As we present the patients included in our survey, we have to underline 2 points: (1) in our country, according to the national standards for

treatment of rectal cancer, it is not obligatory for a neoadjuvant radiotherapy (RT) to be prescribed, and therefore the neoadjuvant modality is strictly individualized; (2) we decided to include in our survey only patients without neoadjuvant RT. Surgical procedures for these patients were consistent with anterior resection for rectal cancer or abdominal-perineal resection. In 2 patients, anterior resection in combination with sigmoidectomy was performed because of the local progression of the carcinomas in upper third of the rectum. Postoperative pathologic examination reported adenocarcinoma in 68 cases, carcinoid tumor in 1 case, stromal tumor (low grade) in 1 case, and malignization of an adenoma in one case.

RESULTS

Three-Dimensional ERUS

A Brüel & Kjær ultrasound system (Nærum, Denmark) with an endoluminal biplane broadband multi-frequency probe was applied. The frequencies of the linear array ranged from 5.5 to 10 MHz, and the frequencies of the convex array ranged from 6 to 16 MHz. Three-dimensional ERUS was used to observe the location, size, and morphology of the lesion, the degree of tumoral invasion of the rectal wall, the relationship between the lesion and the perirectal organs, and the extent of perirectal lymphadenopathy. ERUS was performed preoperatively and was interpreted by one ultrasonographer with experience in endorectal ultrasonography.

The depth of transmural tumor invasion was assessed according to the tumor–node–metastasis (TNM) classifications for both 3-D ERUS and histopathologic examinations, and the results were compared prospectively. The ultrasonographic staging of rectal cancer is as follows: uT1, tumor is limited to 3 layers, and the submucosa is intact; uT2, tumor invades the muscularis propria but does not reach the serosa; uT3, tumor invades the rectal serosa and peripheral tissues; uT4, tumor invades adjacent organs and tissues; uN0, no lymph node

metastasis or obvious lymph nodes are noted around the rectum, or the lymph node diameter is <5 mm; uN1, lymph node metastasis and the lymph node diameter is ≥5 mm.

Routine pathologic examination

Immediately after surgery, resected specimens were opened on the side opposite the tumor and fixed in 10% formalin. After fixation, we obtained serial slices through the whole tumor in Tis–T2 cases or through more than 2 sections of the deepest part of the tumor in T3 or T4 cases. The slices were embedded in paraffin, sectioned, and examined histologically after hematoxylin and eosin (H&E) staining. The resected specimens were morphologically examined by a pathologist. Pathologic T category was identified according to the TNM Rectal Cancer Staging System.

Statistics

The data were expressed as mean ± SD, and the count data were presented as a percentage proportion. The diagnostic accuracy, sensitivity, and specificity of biplane ERUS in the uT staging of rectal cancer were calculated in accordance with the postoperative pathologic results (the latter were considered the gold standard). SPSS 11.0 (IBM Corporation, Armonk, New York, USA) was used to evaluate all data. The κ identity test was applied, and a *P* value <0.05 was considered to be statistically significant.

Results after 3-D ERUS

The morphology of most tumors on ERUS was irregular, with uneven hypoechoic signals inside the tumor and multiple microcalcifications observed in some areas. Tumoral invasion of various layers of the rectal wall was observed. Since malignant tumors characteristically invade along blood vessels, CDFI blood flow distribution can identify the depth of infiltration of the tumor within the rectal

Table 1 Comparison of 3-D ultrasound and postoperative examination according to T Color Doppler Flow Imaging

US staging	Postoperative pathologic staging, n					Overstage	Understage
	pT1	pT2	pT3	pT4	Total		
uT1	13	1			14	7.6%	
uT2	1	27	1		29	3.4%	3.4%
uT3		1	22		23		4.1%
uT4			1	4	5		20%
Total	14	29	24	4	71	2.75%	6.87%

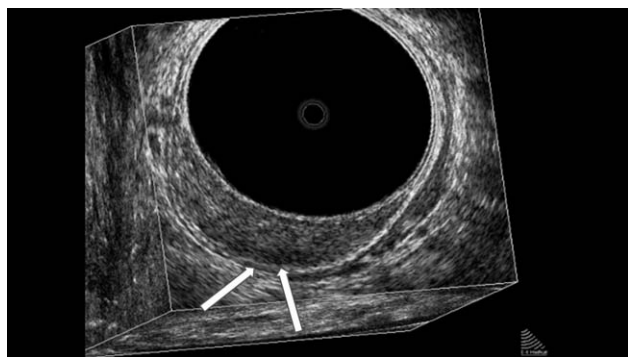


Fig. 1 Three-dimensional ERUS of T1 rectal cancer. The arrows show the penetration of the tumor through the lamina propria and muscularis mucosa layers in the submucosal layer.

wall. Hypervascularity was noted within each tumor, and the arterial blood flow was high impedance [resistive index (RI) = 0.75 ± 0.08]. Enlarged perirectal lymph nodes were found in 19 cases, with diameters ranging from 3.6 to 11.5 mm (mean, 8.4 ± 0.7 mm).

Staging of rectal cancer with 3-D ERUS

Detailed results of the ERUS staging are listed in Table 1. Findings from histopathologic examinations served as the reference standards. Using 3-D ERUS, uT1 was found in 14 cases (Fig. 1), uT2 in 29 cases (Fig. 2), uT3 in 24 cases (Fig. 3), and uT4 in 4 cases (Fig. 4). Three-dimensional ERUS staging agreed

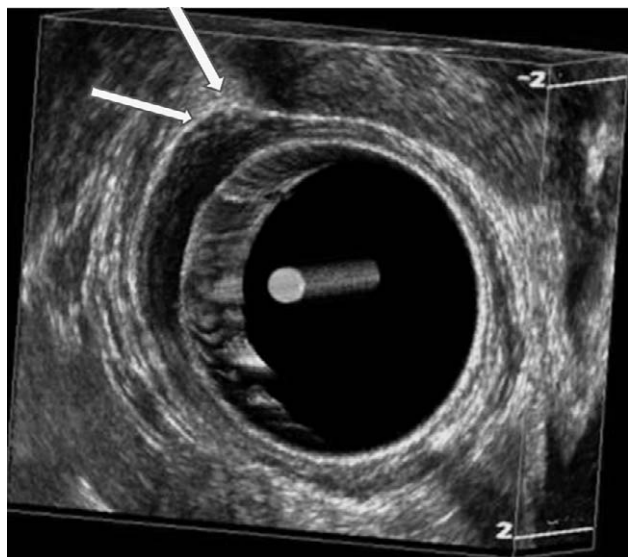


Fig. 2 Three-dimensional ERUS of T2 rectal cancer. The arrows show the penetration of the tumor through the muscularis propria layer.

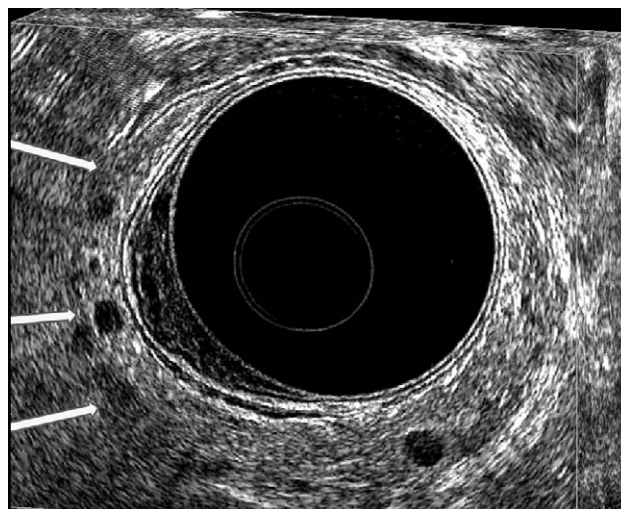


Fig. 3 Three-dimensional ERUS of T3 rectal cancer. The arrows show the penetration of the tumor through the serosal layer.

with the histologic staging in 66 of the 71 (93%) patients, and the agreement on the depth of transmural invasion was good ($\kappa = 0.73$; 95% CI, 0.60–0.86, $P = 0.000$). Accuracy rate, sensitivity, specificity, positive predictive value, and negative predictive value for detection of T1 to T4 categories are shown in Table 2. In one case, a staging error was encountered at T1 (7.6%), and it was overstaged; at T2, one case (3.4%) was overstaged, and one case (3.4%) was understaged; at T3, one case (4.1%) was understaged; and at T4, one case (20%) was understaged. Histologic review of the specimens revealed

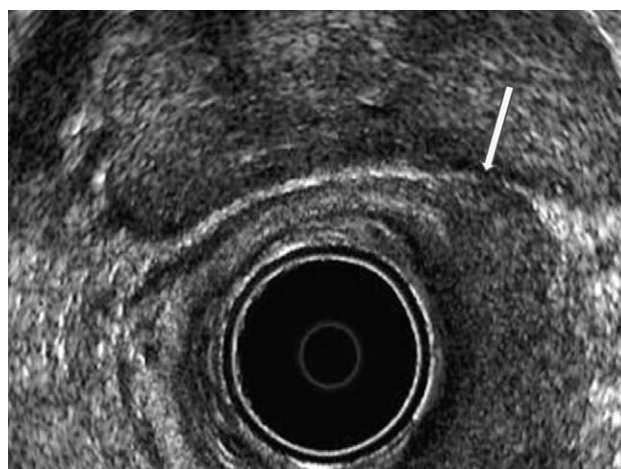


Fig. 4 Three-dimensional ERUS of T4 rectal cancer. The arrows show the penetration of the tumor in the adjacent organ, the prostate.

Table 2 Statistical results from 3-D ERUS in patients with rectal cancer

	pT1	pT2	pT3	pT4
Accuracy	69/71 (97.1%)	67/71 (94.3%)	68/71 (95.7%)	70/71 (98.5%)
Sensitivity	13/14 (92.8%)	27/29 (93.1%)	22/24 (91.6%)	4/4 (100%)
Specificity	56/57 (98.2%)	40/42 (95.4%)	45/46 (97.8%)	66/67 (98.5%)
Positive predictive value	13/14 (92.8%)	27/29 (93.1%)	23/24 (95.8%)	4/5 (80%)
Negative predictive value	56/57 (98.2%)	40/42 (95.4%)	45/47 (95.7%)	67/67 (100%)

that in the total overstaged cases (2.75%), the tumor invaded close to the deeper uninvolved layer, and reactive changes were present in the connective tissue around the tumor including inflammation. Histologic review of understaged cases (6.87%) indicated that they had only microscopic invasion beyond the estimated layers and that reactive changes of the connective tissue around the tumor were slight or absent.

The metastatic status of the lymph nodes was determined with a sensitivity of 79.1% (19 of 24), specificity of 91.4% (43 of 47), and diagnostic accuracy of 87.3% (62 of 71).

Discussion

In a recent meta-analysis,²³ it was found that ERUS was the most accurate modality when compared with CT and MRI for evaluation of local invasion of rectal cancer. However, the accuracy of ERUS examination could be better for N category with numbers between 60% and 80%.²³ The introduction and adoption of 3-D ERUS is an option to increase the results from this easy, inexpensive, and effective diagnostic modality.²⁴

In the current study, the T category on 3-D ERUS correlated with histopathology in 66 of 71 patients (92.9%). The N category on 3-D ERUS correlated with histopathology in 40 of 49 patients (81.6%). Our finding was in concordance with most findings in the literature.^{19,23}

Our results demonstrated that with the reference standards of outcomes from histopathology, detection sensitivities of rectal cancer with 3-D ERUS were as shown in Table 2. Patients with T1 tumors were overstaged twice as often compared with T2 (7.6% versus 3.4%), and more T4 disease was understaged than T3 (20% versus 4.1%). The results of three-dimensional ERUS for T-category for T1, T2, T3 and T4 were 92.8%, 93.1%, 91.6% and 100%, respectively. The T3-patients had the worst results, as confirmed by Ren *et al.*²⁴ The total overstaged cases were 2.75% and the understaged cases were

6.75%. Specificity of 3-D ERUS categorizing from T1 to T4 was almost equal. Our results revealed that 3-D ERUS enabled distinction between early and advanced rectal lesions, and this technique seemed to be more precise in distinguishing between T1 and T2; differentiation between T3 and T4 lesions remained reliable. The results regarding N category remain challenging but are comparable in the literature. The main challenge in proper staging of lymph nodes remains that potentially up to 20% of small nodes could be malignant.² Massari *et al.*²⁵ found that overall accuracy by ERUS in staging the depth of infiltration was 90.7%. Overstaging occurred in 4% of the patients, whereas understaging occurred in 5.3%. In staging lymph node involvement, overall accuracy was 76%, sensitivity was 69.8%, and specificity was 84.4%. These findings were comparable with our results.

Conclusions

Three-dimensional ERUS provides better visual images (even better than those of MRI) of the tumor volume and spatial relations to the adjacent organs and structures, which leads to better diagnostic accuracy than MRI and standard ERUS. The introduction and adoption of 3-D ERUS is an option to optimize results using this easy, inexpensive, and effective diagnostic modality. The most important feature of this upgraded modality is the ability to reduce interpreter errors and offer potential predictive value. The reported data lead to the opinion that 3-D ERUS combines the high-resolution images of the rectal wall and the cost-effectiveness of standard ERUS with the multiplanar and stereoscopic imaging capabilities of MRI. The results from our study and the literature review show that 3-D ERUS is the diagnostic modality of choice in staging of cancer penetration in the rectal wall.

Three-dimensional ERUS may be the future premier imaging modality used in rectal cancer management.

References

- Thaler W, Watzka S, Martin F, La Guardia G, Psenner K, Bonatti G *et al.* Preoperative staging of rectal cancer by endoluminal ultrasound vs. magnetic resonance imaging: preliminary results of a prospective, comparative study. *Dis Colon Rectum* 1994;**37**(12):1189–1193
- Brown G, Davies S, Williams GT, Bourne MW, Newcombe RG, Radcliffe AG *et al.* Effectiveness of preoperative staging in rectal cancer: digital rectal examination, endoluminal ultrasound or magnetic resonance imaging? *Br J Cancer* 2004;**91**(1): 23–29
- Garcia-Aguilar J, Pollack J, Lee SH, Hernandez de Anda E, Mellgren A, Wong WD *et al.* Accuracy of endorectal ultrasonography in preoperative staging of rectal tumors. *Dis Colon Rectum* 2002;**45**(1):10–15
- Marusch F, Koch A, Schmidt U, Zippel R, Kuhn R, Wolff S *et al.* Routine use of transrectal ultrasound in rectal carcinoma: results of a prospective multicenter study. *Endoscopy* 2002; **34**(5):385–390
- Hildebrandt U, Klein T, Feifel G, Schwarz HP, Koch B, Schmitt RM. Endosonography of pararectal lymph nodes: in vitro and in vivo evaluation. *Dis Colon Rectum* 1990;**33**(10):863–868
- Dinter DJ, Hofheinz RD, Hartel M, Kaehler GF, Neff W, Diehl SJ. Preoperative staging of rectal tumors: comparison of endorectal ultrasound, hydro-CT, and high-resolution endorectal MRI. *Onkologie* 2008;**31**(5):230–235
- Moriya Y, Sugihara K, Akasu T, Fujita S. Importance of extended lymphadenectomy with lateral node dissection for advanced lower rectal cancer. *World J Surg* 1997;**21**(7):728–732
- Low G, Tho LM, Leen E, Wiebe E, Kakumanu S, McDonald AC *et al.* The role of imaging in the pre-operative staging and post-operative follow-up of rectal cancer. *Surgeon* 2008;**6**(4):222–231
- Dewhurst C, Rosen MP, Blake MA, Baker ME, Cash BD, Fidler JL *et al.* ACR Appropriateness Criteria pretreatment staging of colorectal cancer. *J Am Coll Radiol* 2012;**9**(11):775–781
- Hunerbein M, Pegios W, Rau B, Vogl TJ, Felix R, Schlag PM. Prospective comparison of endorectal ultrasound, three-dimensional endorectal ultrasound, and endorectal MRI in the preoperative evaluation of rectal tumors: preliminary results. *Surg Endosc* 2000;**14**(11):1005–1009
- Hunerbein M, Totkas S, Moesta KT, Ulmer C, Handke T, Schlag PM. The role of transrectal ultrasound-guided biopsy in the postoperative follow-up of patients with rectal cancer. *Surgery* 2001;**129**(2):164–169
- Ivanov KD, Diavoc CD. Three-dimensional endoluminal ultrasound: new staging technique in patients with rectal cancer. *Dis Colon Rectum* 1997;**40**(1):47–50
- Kim JC, Kim HC, Yu CS, Han KR, Kim JR, Lee KH *et al.* Efficacy of 3-dimensional endorectal ultrasonography compared with conventional ultrasonography and computed tomography in preoperative rectal cancer staging. *Am J Surg* 2006;**192**(1):89–97
- Giovannini M, Bories E, Pesenti C, Moutardier V, Lelong B, Delperro JR. Three-dimensional endorectal ultrasound using a new freehand software program: results in 35 patients with rectal cancer. *Endoscopy* 2006;**38**(4):339–343
- Manger T, Stroh C. Accuracy of endorectal ultrasonography in the preoperative staging of rectal cancer. *Tech Coloproctol* 2004; **8**(suppl 1):14–15
- Bianchi P, Ceriani C, Palmisano A, Pompili G, Passoni GR, Rottoli M *et al.* A prospective comparison of endorectal ultrasound and pelvic magnetic resonance in the preoperative staging of rectal cancer. *Ann Ital Chir* 2006;**77**(1):41–46
- Kim JC, Cho YK, Kim SY, Park SK, Lee MG. Comparative study of three-dimensional and conventional endorectal ultrasonography used in rectal cancer staging. *Surg Endosc* 2002;**16**(9):1280–1285
- Gleeson FC, Clain JE, Rajan E, Topazian MD, Wang KK, Levy MJ. EUS-FNA assessment of extramesenteric lymph node status in primary rectal cancer. *Gastrointest Endosc* 2011;**74**(4): 897–905
- Liersch T, Langer C, Jakob C, Muller D, Ghadimi BM, Siemer A *et al.* Preoperative diagnostic procedures in locally advanced rectal carcinoma (> or =T3 or N+). What does endoluminal ultrasound achieve at staging and restaging (after neoadjuvant radiochemotherapy) in contrast to computed tomography? [In German]. *Chirurg* 2003;**74**(3):224–234
- Worrell S, Horvath K, Blakemore T, Flum D. Endorectal ultrasound detection of focal carcinoma within rectal adenomas. *Am J Surg* 2004;**187**(5):625–629
- Starck M, Bohe M, Simanaitis M, Valentin L. Rectal endosonography can distinguish benign rectal lesions from invasive early rectal cancers. *Colorectal Dis* 2003;**5**(3):246–250
- NIH Consensus Conference. Adjuvant therapy for patients with colon and rectal cancer. *JAMA* 1990;**264**(11):1444–1450
- Bipat S, Glas AS, Slors FJ, Zwinderman AH, Bossuyt PM, Stoker J. Rectal cancer: local staging and assessment of lymph node involvement with endoluminal US, CT, and MR imaging—a meta-analysis. *Radiology* 2004;**232**(3):773–783
- Ren JH, Guo FJ, Dai WD, Han XJ, Ma N. Study of endorectal ultrasonography in the staging of rectal cancer. *Chin Med J (Engl)* 2012;**125**(20):3740–3743
- Massari M, De Simone M, Cioffi U, Rosso L, Chiarelli M, Gabrielli F. Value and limits of endorectal ultrasonography for preoperative staging of rectal carcinoma. *Surg Laparosc Endosc* 1998;**8**(6):438–444

© 2014 Kolev et al; licensee The International College of Surgeons. This is an Open Access article distributed under the terms of the Creative Commons Attribution Non-commercial License, which permits use, distribution, and reproduction in any medium, provided the original work is properly cited, the use is non-commercial and is otherwise in compliance with the license. See: <http://creativecommons.org/licenses/by-nc/3.0>