



Case Report

Considerations for Iliac Vein Repair in the Setting of Urologic Procedures

Kayla J. Krause, Ahsan Zil-E-Ali, Kristine L. So, Faisal Aziz, Aditya Safaya

The Pennsylvania State University, Hershey, PA

Introduction: Iliac vein injuries are associated with high morbidity and mortality, with a feared complication of hemorrhage. We discuss management and the thought process behind mitigating such emergencies.

Case presentation: An 81-year-old Caucasian male was seen intraoperatively by vascular surgery for hemorrhage from an injured left external iliac vein in the setting of left radical nephrectomy and ureterectomy.

Conclusion: Despite initial temporizing efforts by urology, vascular surgical intervention proved necessary in hemostasis, venous reconstruction, and thus, establishing continuity of lower extremity venous drainage.

Key words: External iliac vein – Vascular consultation – Repair – Radical ureterectomy – Urology

Vascular surgeons are often consulted intraoperatively by surgical colleagues, and incidence is increasing.^{1,2} Iliac vein injuries are relatively rare but are associated with significant morbidity and mortality and therefore necessitate repair.³ Iliac vein injury in the context of urologic procedures is not well studied. However, one single-institution study of laparoscopic urologic procedures found that only 1 of 5347 experienced an external iliac vein injury due to initial trocar placement.⁴ Another study found external iliac vein (EIV) injury prevalence was 5% among 41 patients who underwent Argus sling implantation due to postoperative stress urinary incontinence.⁵ Here, we report a case of EIV injury that occurred during a urologic procedure.

Case Presentation

An 81-year-old Caucasian male with stage IV chronic kidney disease (CKD) (glomerular filtration rate: 18 mL/min) and a high-grade T1 bladder cancer treated with Bacillus Calmette-Guerin twice reported to the urology service for high-grade urothelial carcinoma of the left ureter measuring 6.6 cm in length at the level of the left common iliac artery (LCIA) with extension into the ureteral orifice. The patient was brought to the operating room for left radical nephrectomy and ureterectomy. Due to past herniorrhaphy, the patient had extensive adhesions that limited left iliac lymph node dissection, and this led to a venous tear of the left external iliac vein

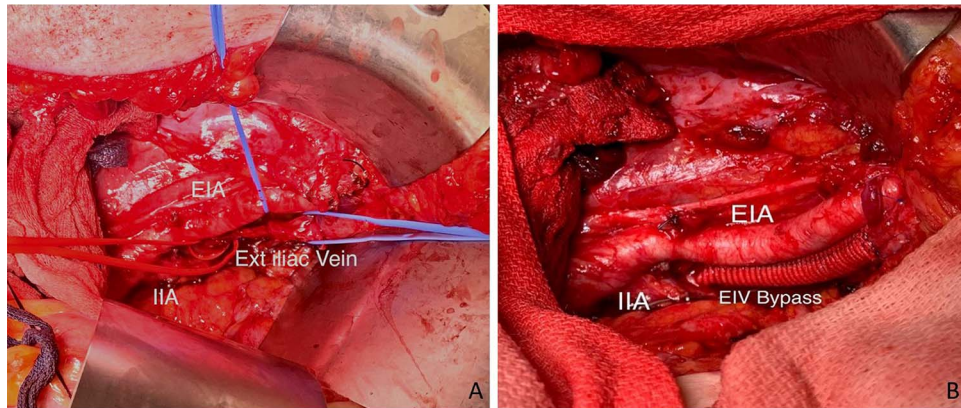


Fig. 1 External iliac vein repair. (A) Significant narrowing of the external iliac vein; (B) External iliac vein bypass graft.

(LEIV) leading to hemorrhage from the LEIV. Initial hemostasis was achieved by the urology team by oversewing the venous injury with running permanent monofilament sutures. Vascular surgery consultation was sought intraoperatively for further evaluation.

The left iliac vessels were exposed proximally up to LCIA and distally to the distal left external iliac artery (LEIA). The LEIV was then identified though its course proximally up to the bifurcation of the left common iliac vein (LCIV) and distally up to the LEIV vein under the inguinal ligament. The previously placed hernia mesh was incised to access the distal LEIV that was adhered to the undersurface of the well-incorporated mesh.

The initial repair of the LEIV was inspected and although it was hemostatic, it had significantly reduced the lumen of the vessel, which was distally dilated and proximally collapsed (Fig. 1A). After discussion with the urology team regarding risks and benefits of restoring iliac vein flow a plan was made to repair the vessel. The patient was systemically heparinized. The LEIV was controlled proximally at the iliac bifurcation and distally at the distal LEIV. A long venotomy was made over the repaired site and thrombectomy was performed until no more clots were expressed and brisk bleeding was observed from the distal and proximal vein. The posterior wall of the vein appeared to be relatively healthy and hence, the vein was repaired with a patch venoplasty using a bovine pericardial patch. Although the repair looked intact, there continued to be a discrepancy of flow through the repaired segment evidenced by a handheld Doppler with lack of phasicity with respiration. Furthermore, the distal LEIV continued to appear dilated with collapse of the proximal venous structures. At this

point, we transected the entire diseased segment of the vein and performed an interposition bypass with an 8 mm Dacron graft (Fig. 1B). Good Doppler flow was appreciated proximal to the repair, on the graft itself, and distal to the repair with good phasicity appreciated on Valsalva and apneic maneuvers. At this point, the urology team returned to finish their part of the procedure.

Postoperatively, the patient was placed on systemic anticoagulation that would continue for 3 months and aspirin (81 mg) daily that was to continue indefinitely. Flow through the graft was preserved, as evidenced by a formal duplex study performed postoperatively. His left lower extremity did not have any swelling and was similar in size to the right throughout the course of his 18-day hospitalization. Unfortunately, given his history of advanced stage renal disease, postoperatively he advanced to acute kidney failure that would require hemodialysis (HD). The patient and his family wished to pursue no further interventions, including HD, and palliative and comfort measures were initiated.

Discussion

Vascular surgeons are collaborative team members and play a crucial role in the management of intraoperative vascular trauma.¹ Given the nature of tumor growth, lymph node involvement, and extranodal spread, it is unsurprising that intraoperative vessel injury has been observed to be most common in cancer surgery.⁶ The adhesion of lymph node tissue to the external iliac vessels in this case increased the risk for vessel tear. In high-risk surgeries, early consultation of vascular surgery is associated with improved outcomes.⁶ Urologic procedures make up about 11% of intraoperative vascular consultations.⁷

The urologic tumors with the highest rates of vascular involvement include 4%–10% venous involvement in renal cell carcinoma, vascular invasion in testicular cancer, and 5%–15% vascular invasion in invasive bladder cancer.^{8–10} However, external iliac vein injury is exceedingly rare, with only one other case report documenting this injury.¹¹ Notably, the injury also occurred in the setting of pelvic lymphadenectomy for bladder cancer.

Iliac vein injuries during nonvascular surgical procedures are rare but may lead to potentially fatal complications including hemorrhage and thrombosis.³ Repair options include vessel ligation, venous patch angioplasty, and vessel bypass. Ligation has shown to be a safe option in the setting of reconstructive surgery or advanced pelvic tumors.¹² Ligation of the common iliac vein is, overall, better tolerated than ligation of the external iliac vein.¹³ The common iliac vein is higher in the pelvis and closer to the vena cava, and typically has better collateral circulation, including the internal iliac veins and lumbar veins. There are also superior venous drainage pathways—ligation of the common iliac vein does not completely obstruct venous outflow, as the internal iliac veins continues to drain into the common iliac vein above the ligation site. The external iliac vein, in contrast, has limited collateral circulation, leading to a more significant disruption of venous blood flow from the lower extremities. This may result in venous congestion, edema, and compromised tissue perfusion. Moreover, ligation of the EIV can increase the risk of lower limb complications including deep vein thromboses leading to pain, swelling, and impaired wound healing, as well as compartment syndrome, venous stasis, and venous hypertension. Thus, repair is overall associated with a lower mortality rate than ligation.³

Choice of venous repair depends on the extent of injury. A small tear at a branching point or a small sharp cut may be primarily repaired with continuous or interrupted nonabsorbable sutures, provided the lumen of the vein is not narrowed. Vein or prosthetic patches may be used in cases when venous wall involvement is more extensive and primary repair may cause significant narrowing of the vein. Venovenous bypasses are restricted to extensive venous injury where more than 50%–75% of the vessel wall is damaged. Autologous grafts such as internal jugular vein, great saphenous vein, or femoral vein may be used if there is a good size match, especially in grossly contaminated or infected fields.¹⁴ Prosthetic grafts such as expanded polytetrafluoroethylene and Dacron use have also been described

and can be used safely and swiftly in clean cases.¹⁵ The authors prefer to size the prosthetic grafts one to one or a size smaller than the external iliac vein diameter.

Though evidence is equivocal, pharmacotherapy is typically used as an adjunct to venous repair, including anticoagulation and antiplatelet therapy. As vein repair increases thrombotic risk, heparin or warfarin prophylaxis is often administered for a period of 3 months.¹⁶ Aspirin is frequently administered after infrainguinal bypass grafting for maintenance of graft patency.¹⁷ The authors prefer a strategy of anticoagulation for at least 3 months, followed by 81 mg aspirin for life.

Despite bleeding control, a narrowed EIV carries high morbidity, including increased risk of deep vein thrombosis, particularly in this patient with cancer with baseline thrombogenic risk.¹⁸ Therefore, even in the absence of ongoing bleeding, this case demonstrates that in cases of vascular injury, vascular consultation remains critical. It has been observed that earlier intervention of vascular surgeons in high-risk procedures is associated with significantly fewer vascular injuries.¹⁹ Particularly as the field of oncovascular surgery evolves, vascular surgical involvement in cancer surgery has been increasing.²⁰

Conclusion

Vascular surgeons are critical members of the team and play a crucial role in the assessment and management of vessel injury during a given primary procedure, even when initial bleeding is controlled. If permitted by patient physiology and hemodynamic stability, repair of external iliac vein should always be considered to prevent postoperative morbidity.

Acknowledgments

The authors declare that they have no financial support or funding to disclose and have no competing financial interests. The authors report no conflicts of interest. All case reports are considered exempt by the Penn State Human Research Protection Program Institutional Review Board.

References

1. Hemingway JF, Desikan S, Dasari M, *et al*. Intraoperative consultation of vascular surgeons is increasing at a major American trauma center. *J Vasc Surg* 2021;74(5):1581–1587

2. Blackwood SL, O'Leary JJ, Scully RE, *et al.* Emergency intra-operative vascular surgery consultations at a tertiary academic center. *J Vasc Surg* 2020;**71**(3):967–978
3. Magee GA, Cho J, Matsushima K, *et al.* Isolated iliac vascular injuries and outcome of repair versus ligation of isolated iliac vein injury. *J Vasc Surg* 2018;**67**(1):254–261
4. Simforoosh N, Basiri A, Ziaee SAM, *et al.* Major vascular injury in laparoscopic urology. *JSLs*. 2014;**18**(3):e2014.00283
5. Cerniauskiene A, Barisiene M, Bakavicius A, Kavaliauskaite R, Cekauskas A, Zelvys A. Complications after male adjustable suburethral sling implantation. *Wideochir Inne Tech Maloinwazyjne* 2020;**15**(3):496–502
6. Yoo TK, Min SK, Ahn S, *et al.* Major vascular injury during nonvascular surgeries. *Ann Vasc Surg* 2012;**26**(6):825–832
7. Danczyk RC, Coleman J, Allensworth J, *et al.* Incidence and outcomes of intraoperative vascular surgery consultations. *J Vasc Surg* 2015;**62**(1):177–182
8. Campbell S, Uzzo RG, Allaf ME, *et al.* Renal Mass and Localized Renal Cancer: AUA Guideline. *J Urol* 2017;**198**(3):520–529
9. Hoeltl W, Kosak D, Pont J, *et al.* Testicular cancer: prognostic implications of vascular invasion. *J Urol* 1987;**137**(4):683–685
10. Shariat SF, Palapattu GS, Karakiewicz PI, *et al.* Discrepancy between clinical and pathologic stage: impact on prognosis after radical cystectomy. *Eur Urol* 2007;**51**(1):137–151
11. Hemal AK, Goel A. External iliac vein injury and its repair during laparoscopic radical cystectomy. *JSLs* 2004;**8**(1):81–83
12. Rajendran S, Brown KGM, Solomon MJ. Oncovascular surgery for advanced pelvic malignancy. *Br J Surg* 2023;**110**(2):144–149
13. Manley NR, Magnotti LJ, Fabian TC, Croce MA, Sharpe JP. Impact of venorrhaphy and vein ligation in isolated lower-extremity venous injuries on venous thromboembolism and edema. *J Trauma Acute Care Surg* 2018;**84**(2):325–329
14. Dorweiler B, Neufang A, Chaban R, Reinstadler J, Duenschede F, Vahl CF. Use and durability of femoral vein for autologous reconstruction with infection of the aortoiliiofemoral axis. *J Vasc Surg* 2014;**59**(3):675–683
15. Vaughan GD, Mattox KL, Feliciano DV, Beall AC, DeBakey ME. Surgical experience with expanded polytetrafluoroethylene (PTFE) as a replacement graft for traumatized vessels. *J Trauma* 1979;**19**(6):403–408
16. Franz RW, Shah KJ, Halaharvi D, Franz ET, Hartman JF, Wright ML. A 5-year review of management of lower extremity arterial injuries at an urban level I trauma center. *J Vasc Surg* 2011;**53**(6):1604–1610
17. Maufus M, Pernod G. Antithrombotic therapy after infringuinal bypass. *J Vasc Surg* 2014;**60**(5):1367–1375
18. Prins MH, Lensing AWA, Brighton TA, *et al.* Oral rivaroxaban versus enoxaparin with vitamin K antagonist for the treatment of symptomatic venous thromboembolism in patients with cancer (EINSTEIN-DVT and EINSTEIN-PE): a pooled subgroup analysis of two randomised controlled trials. *Lancet Haematol* 2014;**1**(1):e37–e46
19. Mogannam AC, Chavez De Paz C, Sheng N, *et al.* Early Vascular consultation in the setting of oncologic resections: benefit for patients and a continuing source of open vascular surgical training. *Ann Vasc Surg* 2015;**29**(4):810–815
20. Han A, Ahn S, Min SK. Oncovascular surgery: essential roles of vascular surgeons in cancer surgery. *Vasc Specialist Int* 2019;**35**(2):60–69