



Case Report

Successful Management of Advanced Gastric Cancer With Bulky Lymph Node Metastases and Tumor Thrombus in the Portal Vein System: A Case Report

Yukinori Yamagata¹, Kazuyuki Saito¹, Kosuke Hirano¹, Ryuji Yoshioka¹, Takashi Okuyama¹, Emiko Takeshita¹, Akiko Fujii², Shinichi Ban², Nobumi Tagaya¹, Shinichi Sameshima¹, Tamaki Noie¹, Takehiko Yamaguchi², Masatoshi Oya¹

¹*Department of Surgery, Dokkyo Medical University Saitama Medical Center, Saitama, Japan*

²*Department of Pathology, Dokkyo Medical University Saitama Medical Center, Saitama, Japan*

Background: Gastric cancer cases with tumor thrombus in the portal vein system (PVT) are rare, frequently develop liver metastasis, and have a very poor prognosis.

Case presentation: A 65-year-old man presented to a physician with a complaint of upper abdominal pain persisting for 2 months. Esophagogastroduodenoscopy revealed a Borrmann type 2 tumor, and he was referred to our hospital. Computed tomography (CT) showed wall thickening of the stomach, bulky swelling of lymph nodes in the lesser curvature and along the pancreas body, and tumor thrombus in the splenic to the portal vein. CT showed no liver or lung metastases, ascites, or peritoneal nodules. Staging laparoscopy revealed P0CY0. We planned to administer neoadjuvant chemotherapy (NAC), consisting of 2 courses of TS-1 and cisplatin combined chemotherapy. However, the second course of the chemotherapy was canceled on day 8 because of influenza. CT after chemotherapy showed no remarkable change, but we decided to undertake the planned operation. Total gastrectomy and pancreaticosplenectomy, along with lymphadenectomy, thrombectomy, and cholecystectomy, was performed. The patient was discharged on postoperative day 12 without complications. Histopathologic examination showed a well to moderately differentiated adenocarcinoma with 45 lymph node metastases. The specimen of the tumor thrombus also showed a moderately differentiated adenocarcinoma. Because

Corresponding author: Yukinori Yamagata, MD, PhD, Department of Surgery, Dokkyo Medical University Saitama Medical Center, 2-1-50 Minami-Koshigaya, Koshigaya City, Saitama 343-8555, Japan.
Tel.: +8148-965-1111; Fax: +8148-965-1130; E-mail: yamagay-ky@umin.ac.jp

he did not want additional chemotherapy, we selected follow-up observation. The patient has remained disease-free for 60 months after the operation.

Conclusion: We described a patient with advanced gastric cancer with PVTT, who could undergo R0 resection with a good clinical course.

Key words: Gastric cancer – Tumor thrombus – Bulky lymph node metastases

In gastric cancer patients, formation of tumor thrombus (TT) in the portal vein system (PVTT) is rare, affecting only 1.2% of the total patient population.^{1,2} Furthermore, gastric cancer cases with PVTT frequently develop liver metastasis and have a very poor prognosis.¹

Here we report a patient with advanced gastric cancer with bulky lymph node metastases and PVTT, who underwent R0 resection following neo-adjuvant chemotherapy (NAC) with a good clinical course.

Case Presentation

A 65-year-old man presented to a physician with a complaint of upper abdominal pain persisting for 2 months. Esophagogastroduodenoscopy (EGD) revealed a Borrmann type 2 tumor, and he was referred to our hospital for detailed examination. He had a history of bronchial asthma and lung cancer, and had undergone left lower lobectomy 2 years prior to admission. Laboratory data on admission showed no remarkable findings, without an elevation of carbohydrate antigen 19-9 level (61.9 U/mL).

EGD showed a large Borrmann type 2 tumor in the gastric cardia with a slight invasion into the esophagus. A biopsy specimen revealed poorly differentiated adenocarcinoma. Contrast-enhanced computed tomography (CT) showed a thickening of the upper wall of the stomach, bulky swelling of lymph nodes in the lesser curvature and along the pancreas body, and tumor thrombus in the splenic to the portal vein (Fig. 1). CT showed no liver or lung metastases, ascites, or peritoneal nodules.

We determined that the tumor could be resectable via thrombectomy. Thus, staging laparoscopy was performed to exclude peritoneal dissemination, and revealed P0CY0. We planned to administer NAC, consisting of 2 courses of TS-1 and cisplatin combination chemotherapy (TS-1 100 mg/day on day 1–27, cisplatin 60 mg/m² on day 8), before the operation. However, the second course of chemotherapy was canceled on day 8 because of influenza.

CT after chemotherapy showed no remarkable change since before NAC, but we decided to proceed with the operation as planned. Total gastrectomy and pancreaticosplenectomy with D2 + No 14 (lymph nodes along the superior mesenteric vein and artery) lymphadenectomy, thrombectomy, and cholecystectomy, were performed (Fig. 2). The patient was discharged on postoperative day 12 after the operation without complications.

Histopathologic examination of the resected specimen revealed that the primary 87 × 45 mm lesion was a well to moderately differentiated adenocarcinoma with 45 lymph node metastases (including No. 14 lymph nodes), and it was diagnosed as a stage IV tumor (according to the Union for International Cancer Control TNM classification, 7th edition). The specimen of the tumor thrombus also showed moderately differentiated adenocarcinoma. We suggested additional chemotherapy, but as the patient refused, we selected follow-up observation. The patient has remained disease-free for 60 months after the operation until the present day.

Discussion and Conclusion

In gastric cancer patients, formation of PVTT is rare, affecting only 1.2% of cases.^{1,2} Furthermore, gastric cancer patients with PVTT are expected to develop liver metastasis at a high frequency. Indeed, Eom *et al*¹ reported that 72.5% (37/51) of patients with PVTT had liver metastasis and the median survival of these gastric cancer patients was reported to be 5.4 months, a very poor prognosis.¹

Hepatocellular carcinoma (HCC) is a tumor capable of producing PVTT. As a disease similar to HCC, alpha-fetoprotein (AFP) producing gastric cancer, namely hepatoid adenocarcinoma with hepatic differentiation, sometimes produces PVTT.^{3,4} However, in our case, immunohistochemistry of the resected tissue specimen stained negative for AFP.

There have been some reports describing cases with a long-term survival, but all of these cases achieved R0

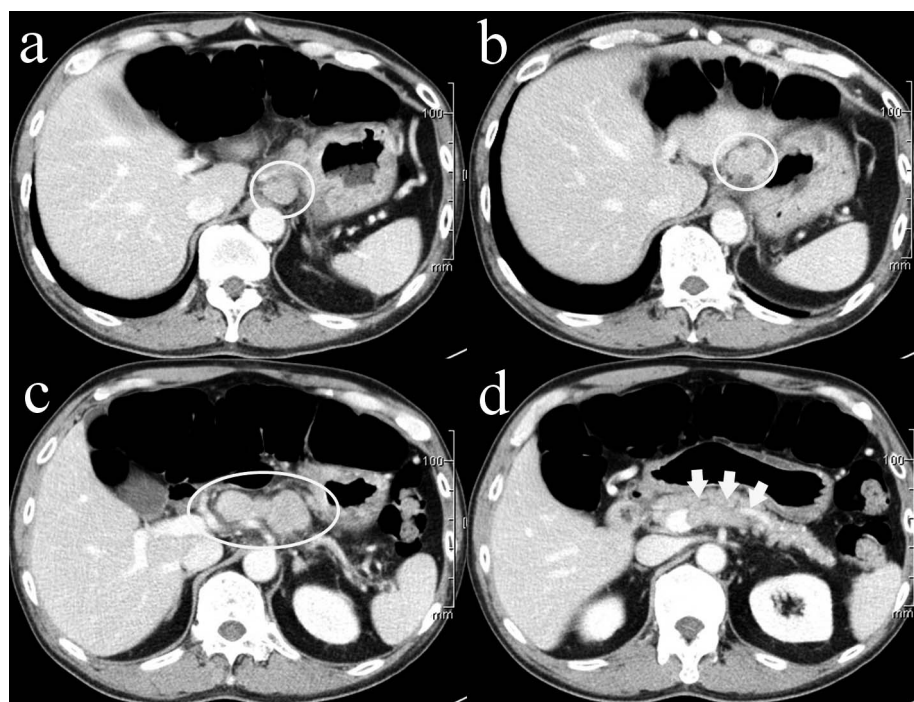


Fig. 1 Contrast-enhanced CT findings. (a) CT shows the wall thickening of the upper side of the stomach and bulky swelling of lymph nodes in the lesser curvature. (b) CT shows bulky swelling of lymph nodes in the lesser curvature. (c) CT shows bulky swelling of lymph nodes along the pancreas body. (d) CT shows tumor thrombus in the splenic to the portal vein.

resection with no distant metastases, or had metastases controllable by chemotherapy.⁴⁻⁷ Even in highly advanced gastric cancer cases with PVTT, if other poor prognostic factors do not exist or are under control, aiming at R0 resection is thought to be the only way to achieve a cure. Although careful preoperative diagnosis is necessary, in cases in where R0 resection is

judged to be possible, a surgical approach should be attempted.

There are a few reports in which splenic metastasis or PVTT has disappeared in response to chemotherapy, and long-term survival was obtained by then applying conversion surgery.^{4,5} However, according to the report by Eom *et al*,¹ although

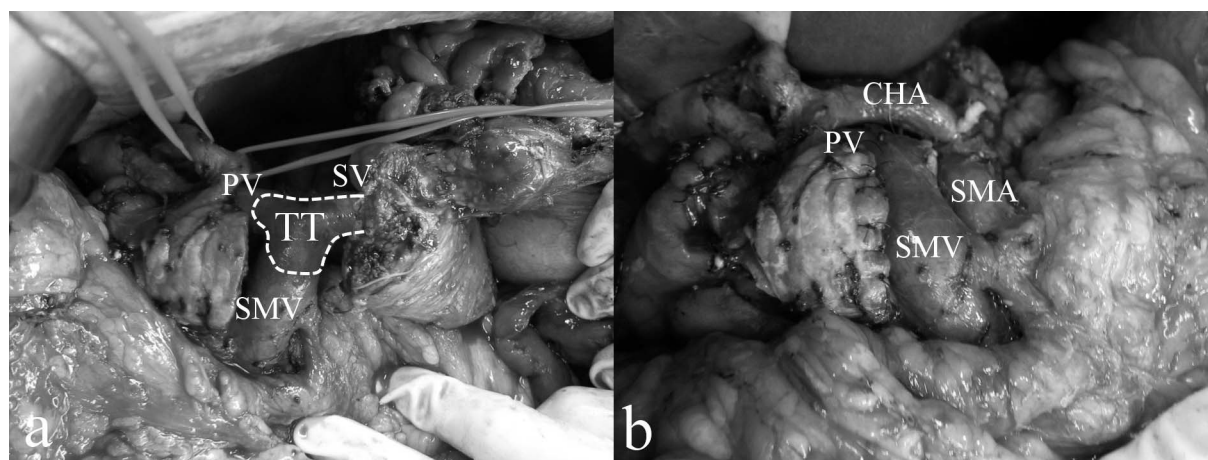


Fig. 2 Intraoperative findings. (a) There was a tumor thrombus in the portal vein system. PV: portal vein, SV: splenic vein, SMV: superior mesenteric vein. (b) After removal of the tumor thrombus from the splenic vein. SMA: superior mesenteric artery, CHA: common hepatic artery.

chemotherapy was performed in 43 of 51 cases, the median survival was only 5.4 months, and therefore the effect of chemotherapy for gastric cancer patients with PVTT is thought to be limited. Nonetheless, in inoperable cases, there is no treatment other than chemotherapy, and new regimens and drugs are necessary.

In gastric cancer patients with PVTT who have a poor prognosis, and in whose cases resection may be questionable, the treatment strategy of trying to improve the possibility of R0 resection by introducing NAC seems to be acceptable.

However, the propriety of gastrectomy for stage IV gastric cancer is highly controversial.⁸ Although some papers argued that gastrectomy contributed to the survival of stage IV gastric cancer patient or better outcomes were observed in selected patient subgroups of stage IV gastric cancer, indication of gastrectomy for stage IV gastric cancer should be judged carefully.^{9,10}

In this case, the CT scan showed advanced lymph node metastases and PVTT, but no obvious liver/lung metastasis or ascites were observed. Staging laparoscopy was performed and confirmed stage P0CY0, and NAC was administered. Although the NAC could not be completed due to influenza and effective tumor shrinkage could not be obtained, R0 resection could be performed and the patient has remained disease-free 60 months after the operation until the present day.

We experienced a rare advanced gastric cancer case with PVTT. We performed radical surgery after NAC and obtained a good clinical course.

Acknowledgments

We performed this case report in accordance with the Declaration of Helsinki and the ethics committee of the Dokkyo Medical University Koshigaya Hospital. Written informed consent was obtained from the patient for publication of this case report and accompanying images. A copy of the written consent is available for review by the Editor of the journal. All available data are presented in the case. The authors declare that they have no competing interests and no funding was provided. All authors

have been involved in the management of the patient and in the conception of the manuscript. YY has been involved in the drafting of the manuscript and its critical revision for important intellectual content. All authors read and approved the final manuscript.

References

1. Eom BW, Lee JH, Lee JS, Kim MJ, Ryu KW, Choi IJ *et al.* Survival analysis of gastric cancer patients with tumor thrombus in the portal vein. *J Surg Oncol* 2012;**105**(3):310–315
2. Tanaka A, Takeda R, Mukaihara S, Hayakawa K, Takasu K, Terajima H, Yamaoka Y, Chiba T. Tumor thrombi in the portal vein system originating from gastrointestinal tract cancer. *J Gastroenterol* 2002;**37**(3):220–228
3. Araki T, Suda K, Sekikawa T, Ishii Y, Hihara T, Kachi K. Portal venous tumor thrombosis associated with gastric adenocarcinoma. *Radiology* 1990;**174**(3 Pt 1):811–814
4. Nakao S, Nakata B, Tendo M, Kuroda K, Hori T, Inaba M *et al.* Salvage surgery after chemotherapy with S-1 plus cisplatin for α -fetoprotein-producing gastric cancer with a portal vein tumor thrombus: a case report. *BMC Surg* 2015;15:5
5. Ishigami S, Arigami T, Okubo K, Sasaki K, Kurahara H, Uenosono Y *et al.* Successful treatment of advanced gastric adenocarcinoma with portal tumor thrombosis by total gastrectomy following CDDP and S-1 therapy. *Clin J Gastroenterol* 2012;**5**(3):230–233
6. Furui J, Enryoji A, Okudaira S, Takayama K, Kanematsu T. Successful surgical treatment of gastric cancer with a tumor thrombus in the portal and splenic veins: Report of a case. *Surg Today* 1998;**28**(10):1046–1050
7. Sugawara Y, Konishi T, Hiraishi M, Ishizaki Y, Makuuchi M. Portal tumor thrombi due to gastric cancer. *Hepatogastroenterology* 1996;**43**(10):000–1005
8. Lasithiotakis K, Antoniou SA, Antoniou GA, Kaklamanos I, Zoras O. Gastrectomy for stage IV gastric cancer. a systematic review and meta-analysis. *Anticancer Res* 2014;**34**(5):2079–2085
9. He X, Lai S, Su T, Liu Y, Ding Y, Quan S *et al.* Survival benefits of gastrectomy in gastric cancer patients with stage IV: a population-based study. *Oncotarget* 2017;**8**(63):106577–106586
10. Lim S, Muhs BE, Marcus SG, Newman E, Berman RS, Hiotis SP. Results following resection for stage IV gastric cancer; are better outcomes observed in selected patient subgroups? *J Surg Oncol* 2007;**95**(2):118–122