



Case Report

Laparoscopic Hand-Assisted Adrenal-Sparing Surgery for a Giant Adrenal Myelolipoma: A Case Report

Bong Hee Park¹, Su Lim Lee², Kyung Jin Seo³, Sang Rak Bae¹, Yong Seok Lee¹, Sung Hak Kang¹, Chang Hee Han¹

Departments of ¹Urology, ²Radiology, and ³Hospital Pathology, Uijeongbu St. Mary's Hospital, College of Medicine, The Catholic University of Korea, Uijeongbu, Korea

Adrenal myelolipoma is a rare, benign tumor. Surgical resection is advocated in symptomatic cases, large (size >4 cm) cases, cases where there is an increase in size on follow-up, and cases with an atypical appearance on imaging. Laparoscopic adrenalectomy is currently the gold standard operation for managing benign adrenal mass. However, to date, laparoscopic entire resection of ipsilateral adrenal gland with the tumor has mainly been reported in the literature. Under clinical circumstances, adrenal-sparing surgery is underused as first-line therapy for adrenal tumors. We present a case of adrenal myelolipoma involving the right adrenal gland of a 45-year-old woman who presented with right-sided flank pain. On radiologic and endocrine evaluation, she received a diagnosis of a giant adrenal myelolipoma (>8 cm). Right hand-assisted laparoscopic partial adrenalectomy was performed, and postoperative recovery was uneventful. Finally, histologic examination confirmed adrenal myelolipoma. On follow-up computed tomography, there was no residual tumor and the remaining right adrenal gland. Our report suggests that hand-assisted laparoscopic partial adrenalectomy could be considered for appropriate removal of adrenal myelolipoma, even in giant adrenal myelolipoma.

Key words: Adrenalectomy – Adrenal glands – Hand-assisted laparoscopy – Myelolipoma

Adrenal myelolipomas are rare, benign, non-functional tumors composed of mature adipose tissue and hematopoietic elements.¹ Surgery is indicated when a tumor is symptomatic, large in size (>4 cm), has an atypical appearance on imaging, and increases in size during follow-up.² Laparoscopic adrenalectomy is currently the gold standard operation for managing benign adrenal masses, including adrenal myelolipoma.³ However, adrenal-sparing surgery is underused as first-line therapy for adrenal tumors. Here, we present a case that applied a hand-assisted laparoscopic partial adrenalectomy to treat a giant adrenal myelolipoma (>8 cm).

Case Report

A 45-year-old woman presented to a district hospital with right-sided flank pain that had persisted for 1 month. She had a 10-year history of type 2 diabetes mellitus, for which she was receiving an oral hypoglycemic agent. Contrast-enhanced computed tomography (CT) revealed a well-circumscribed, nonhomogenous retroperitoneal mass with soft tissue attenuation (11 HU) and fat attenuation (−94 HU) that measured 8.3×6.0 cm in the right suprarenal region. The patient was then referred to our hospital for further evaluation and management.

Physical examination of the patient was nonspecific. Adrenal endocrinologic evaluation of urine and blood showed levels within normal limits, including the plasma metanephrine level for excluding pheochromocytoma, plasma aldosterone to renin activity ratio for excluding hyperaldosteronism, and 24-hour urinary cortisol for excluding Cushing syndrome. Magnetic resonance image (MRI) showed a well-defined mass that measured 8.5×6.2 cm, had a high signal intensity (white arrow) on T2-weighted image, and had a low signal intensity (black arrow) on T1-enhanced, fat-suppressed image, which partially obliterated the right

adrenal gland (Fig. 1, arrowhead). Radiologic impression suggested right adrenal myelolipoma.

The patient underwent a right hand-assisted laparoscopic partial adrenalectomy because the tumor was large and symptomatic. Surgery was performed, applying the transperitoneal approach in a 45° lateral flank position. A right lower quadrant incision 8 cm in length was placed for a hand port, and the Dextrus Endopath (Ethicon Endo-Surgery LLC, Guaynabo, Puerto Rico) was fitted through the incision. Three additional trocars (11-mm trocar for the camera; 5-mm trocars for the operating instruments) were then inserted. A camera port was placed in the right midclavicular line at the umbilicus level. One 5-mm port was placed at the 9-cm cephalad camera port along the midclavicular line, and the other was inserted below the costal margin at the midline for liver retraction. After the pneumoperitoneum was established, the liver was retracted upwards and the colon was mobilized. After detection of a well-encapsulated mass in the right adrenal gland, we identified a well-demarcated tissue plane between the anterior limb of the right adrenal gland and the mass. Hence, we carefully dissected the mass away from the anterior limb of the right adrenal gland with an ultrasonic scalpel, and the tumor was completely extracted by an endobag with preservation of the anterior limb of the right adrenal gland. The operation time was 110 minutes and estimated blood loss was 50 mL.

Macroscopic examination of the specimen revealed that the tumor was a rounded and well-encapsulated mass that measured 9.0×8.5 cm, with a smooth external surface. The cut surface showed a variegated appearance, with red-brown and yellowish areas (Fig. 2).

Microscopic examination revealed that the tumor was composed of mature adipose tissue and hematopoietic tissue without signs of cytologic atypia, and was surrounded by normal adrenal cortical tissue and a fibrous capsule (Fig. 3). These

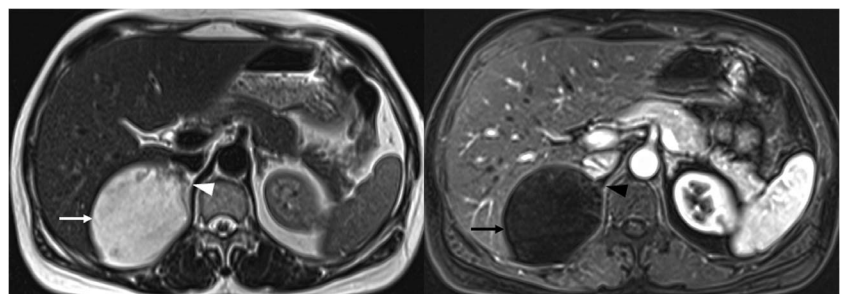


Fig. 1 MRI shows adrenal myelolipoma (arrow) and the adrenal gland (arrowhead).

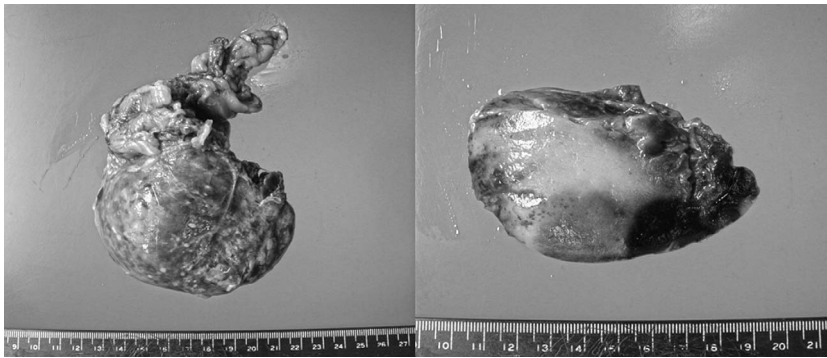


Fig. 2 Macroscopic aspect of resected specimen shows well-encapsulated tumor, and cut surface of the specimen shows a variegated appearance of red-brown and yellowish areas.

findings confirmed the initial diagnosis of adrenal myelolipoma.

The patient had an uneventful postoperative recovery. At 1-year follow-up she remained pain free; follow-up CT showed no residual tumor and the remaining right adrenal gland (Fig. 4). Follow-up adrenal hormonal evaluations were within normal ranges.

Discussion

Adrenal myelolipoma is a rare, benign tumor that is composed of mature adipocytes and hematopoietic elements. This tumor was first described by Gierke in 1905 and designated as myelolipoma by Oberling in 1929.⁴ In the past, adrenal myelolipoma was primarily detected at autopsy, and incidences ranged from 0.08% to 0.4%.¹ Recently, with the widespread use of various imaging modalities, such as ultrasonography, CT, and MRI, incidental detection of adrenal myelolipoma has become more common (10%–15%).⁵

Several theories have been suggested for the pathogenesis of adrenal myelolipoma; however, the most widely accepted tumorigenesis hypothesis is metaplasia of the reticuloendothelial cells of blood capillaries in the adrenal gland in response to such stimuli as infection, stress, or necrosis.⁶

Ultrasonography, CT, and MRI are all effective for diagnosing more than 90% of adrenal myelolipomas. CT is the most sensitive for adipose tissue detection, with negative attenuation values. MRI does not add significantly to adrenal myelolipoma tissue characterization; however, it could help in distinguishing the tumor origin and assessing tissue planes for surgical planning.⁵ Differential diagnosis should include renal angiomyolipoma, retroperitoneal lipoma, liposarcoma, teratoma, adrenal metastasis, adrenal adenoma, and adrenal carcinoma. If there

are any doubts about adrenal myelolipoma diagnosis, an endocrine evaluation should be performed.

Adrenal myelolipoma should be managed on an individual basis. Treatment of small (≤ 4 cm), asymptomatic adrenal myelolipoma involves follow-up with imaging studies. Indications for surgery include symptoms, large size (>4 cm), increase of size on follow-up, and atypical appearance on imaging.² The gold standard operation for adrenal diseases since the 1990s has been laparoscopic surgery. However, for many years a large adrenal tumor (>6 cm) was considered a contraindication for laparoscopic surgery. Several recent studies have reported that laparoscopic surgeries are technically feasible, safe, and show outcomes comparable with the open approach.^{7,8} Historically, unilateral total adrenalectomy has been the standard treatment for unilateral benign adrenal tumor. Until now, there

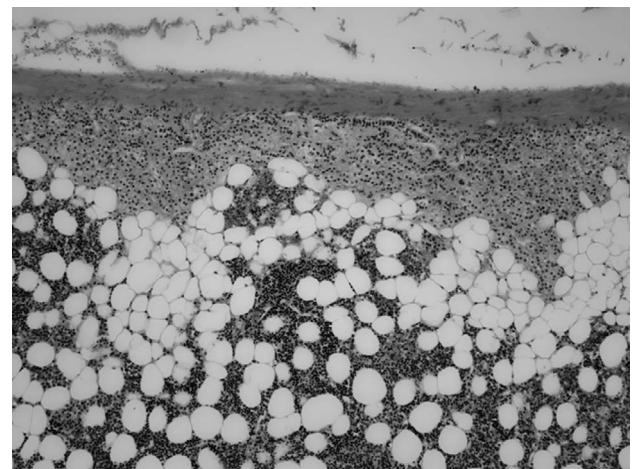


Fig. 3 Microscopic examination of section stained with hematoxylin-eosin ($\times 100$) shows a typical myelolipoma composed of mature adipose tissue and hematopoietic tissue, which is surrounded by normal adrenal cortical tissue and a fibrous capsule.

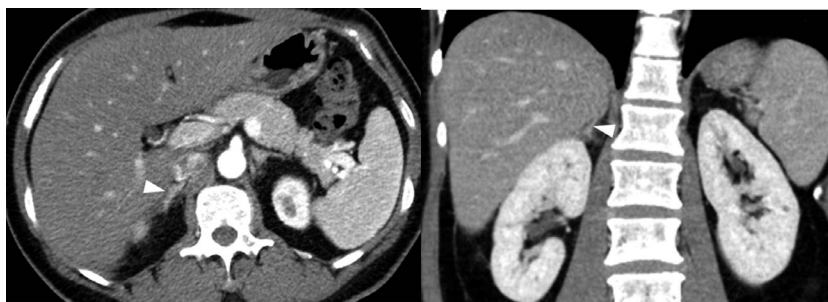


Fig. 4 Postoperative contrast-enhanced CT shows the remaining adrenal gland (arrowhead).

have been reported laparoscopic surgeries involved removing the ipsilateral adrenal gland and the tumor together, regardless of size of adrenal myelolipoma in the literature. However, in recent years, some groups recommended performing adrenal-sparing surgery to avoid the potential risks and complications of adrenal insufficiency and hormonal supplementation in selected cases.^{9,10} Adrenal-sparing surgeries have been performed in patients with bilateral benign tumors or a solitary adrenal gland, as well as a normal contralateral adrenal gland.⁹ In our case, the patient had a large adrenal tumor (>4 cm) with right-sided flank pain. MRI suggested adrenal myelolipoma the tissue plane between the anterior portion of adrenal gland and the tumor was well defined, and adrenal hormonal evaluation results were within normal ranges. The patient underwent hand-assisted laparoscopic partial adrenalectomy. For our patient, hand-assisted laparoscopic surgery was preferable to pure laparoscopic surgery because it allows for more effective traction of surrounding tissues and more distinct demarcation between the tumor and the adrenal gland.

In conclusion, our experience suggests that hand-assisted laparoscopic partial adrenalectomy is effective and safe in appropriately selected adrenal myelolipoma. From the perspective of maximal organ preservation and preclusion of hormonal replacement, if technically feasible, adrenal-sparing

surgery should be considered as an option, albeit for patients with giant adrenal myelolipoma.

References

1. Olsson CA, Krane RJ, Klugo RC, Selikowitz SM. Adrenal myelolipoma. *Surgery* 1973;73(5):665–670
2. Meyer A, Behrend M. Presentation and therapy of myelolipoma. *Int J Urol* 2005;12(3):239–243
3. Castillo O, Sanchez-Salas R, Vidal I. Laparoscopic adrenalectomy. *Minerva Urol Nefrol* 2008;60(3):177–184
4. Oberling C. The formation of myelolipomas. *Bull Assoc Fr Etud Cancer* 1929;18(3):234–246
5. Daneshmand S, Quek ML. Adrenal myelolipoma: diagnosis and management. *Urol J* 2006;3(2):71–74
6. Meaglia JP, Schmidt JD. Natural history of an adrenal myelolipoma. *J Urol* 1992;147(4):1089–1090
7. Gershuni VM, Bittner JG IV, Moley JF, Brunt LM. Adrenal myelolipoma: operative indications and outcomes. *J Laparoendosc Adv Surg Tech A* 2014;24(1):8–12
8. Yin L, Teng J, Zhou Q, Liu Y, Yao Y, Gao Y *et al.* A 10-year single-center experience with surgical management of adrenal myelolipoma. *J Endourol* 2014;28(2):252–255
9. Kaye DR, Storey BB, Pacak K, Pinto PA, Linehan WM, Bratslavsky G. Partial adrenalectomy: underused first line therapy for small adrenal tumors. *J Urol* 2010;184(1):18–25
10. Munver R, Del Pizzo JJ, Sosa RE. Adrenal-preserving minimally invasive surgery: the role of laparoscopic partial adrenalectomy, cryosurgery, and radiofrequency ablation of the adrenal gland. *Curr Urol Rep* 2003;4(1):87–92