



Case Report

Surgical Removal of an Intracardiac Sewing Needle in a 13-Month-Old Chinese Girl: Report of a Case

Xiangyang Dong, Bo Zhai, Wenjing Li, Yazhou Cui, Zhenliang Chen, Penggao Wang

Department of Cardiothoracic Surgery, Children's Hospital of Zhengzhou, Zhengzhou, People's Republic of China

Sewing needles, albeit rare in the case of penetrating cardiac injury, are highly lethal; especially in children, because the injury is difficult to diagnose and treat. We herein present the case of a 13-month-old girl who was injured by a sewing needle inserted in the myocardium; it is the first report of its kind from mainland China. The 13-month-old girl was referred to our hospital with a range of symptoms, including convulsions, diarrhea, and cough. Chest X-ray and echocardiogram revealed a needle located below the aortic valve, passing through the ventricular septum and aortic root. Surgical removal of the needle was performed under extracorporeal circulation. No hemorrhage or arrhythmia was seen, so the operation was ended, and the patient was discharged 8 days after the surgery. An early diagnosis and intervention proved to be lifesaving for this patient with a penetrating cardiac injury. We hope this case can provide a reference for the treatment of similar situations.

Key words: Cardiac function – Foreign body – Pediatric – Patient safety – Surgery

A needle in the heart is a comparatively rare event. It is typically considered to be life threatening as it may induce adverse events such as cardiac tamponade, infection, mural thrombus, peripheral embolism, and valve dysfunction. Especially in children, a sharp needle in the heart poses a serious hazard requiring immediate intervention. However, because of the limited communication

skills of children, it is difficult to make a timely and accurate diagnosis, which adds complexity to the treatment. To date, no similar cases have been reported from China. In this report, we present a case of a child who had a sewing needle inserted in the myocardium. The needle was successfully extracted under extracorporeal circulation.

Corresponding author: Bo Zhai, MD, Department of Cardiothoracic Surgery, Children's Hospital of Zhengzhou, No. 255 Gang Du Avenue, Zhengzhou 450000, People's Republic of China.

Tel.: +86 1383 8383178; Fax: +86 0371 63943790; E-mail: zhaibo3000@163.com

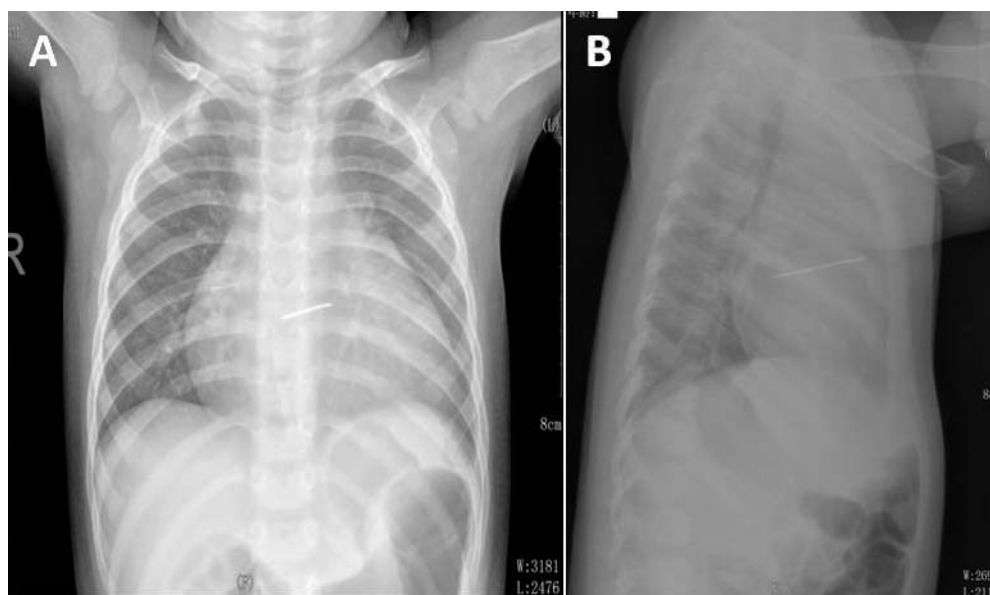


Fig. 1 Chest X-ray examination showed a needle-shaped metallic density within the cardiac silhouette. (A) Postero-anterior view. (B) Left lateral view.

Case Report

A 13-month-old girl with the manifestation of diarrhea was admitted to a local hospital, and the symptoms of diarrhea were relieved after taking some medications, which are unknown. Two days later, she suffered from diarrhea again and was prescribed some traditional Chinese medicine (TCM), the components of which were also unknown. However, the child went into convulsions 12 hours after intake of the TCM, and the convulsions lasted for approximately 2 minutes. Four hours later, the patient developed fever, accompanied with a nonprojectile vomiting. Emergency examination revealed elevated serum myocardial enzymes and bradycardia. Vitamin C, cephalosporins, mannitol, and cimetidine were prescribed for treatment. Although bradycardia was relieved, the rest of the above symptoms remained after a week of treatment. A productive cough also appeared subsequently. The child was then transferred to our institution for further management.

On examination, her vital signs were stable. Results of routine blood and urine analyses as well as serum cardiac enzymes were normal. The respiratory sound of the patient was rough, and there were rales as well as expiratory wheeze during lung auscultation. A routine chest X-ray and cranial computed tomography (CT) were performed because the symptoms were persistent. We incidental-

ly found a linear metallic mediastinal foreign body (FB) located within the cardiac shadow (Fig. 1). No abnormality was detected by CT scan of the head (data not shown). Echocardiogram showed that the metallic FB was located below the aortic valve, passing through the ventricular septum and aortic root, with the eye point reaching the right ventricle and left atrium (Fig. 2). Mild pericardial effusion was also presented. Some scattered floccus could also be seen near the posterior wall of the left ventricle on ultrasound as a hyperechoic area.

Based on the above findings, the surgical removal of the FB was performed with the heart beating. Under extracorporeal circulation, we approached the FB with a median sternotomy. A small amount of blood (approximately 100 mL) was seen in the cardiac sac and was drained. The surface of the heart was found to be covered with a layer of cellulose-like substance, especially at the area of right ventricular outflow tract (RVOT), and one puncture site was also observed in the RVOT. With the beating of the heart, a small amount of blood was discharged intermittently from the pinhole. Because neither end of the needle was denuded, an incision was made into the right atrium, which was nearby the arterial septum. The needle appeared to have migrated through the right ventricle and ventricular septum and almost pierced through the posterior wall of the left atrium. A sewing needle of 5 cm in length and 1 mm in thickness was

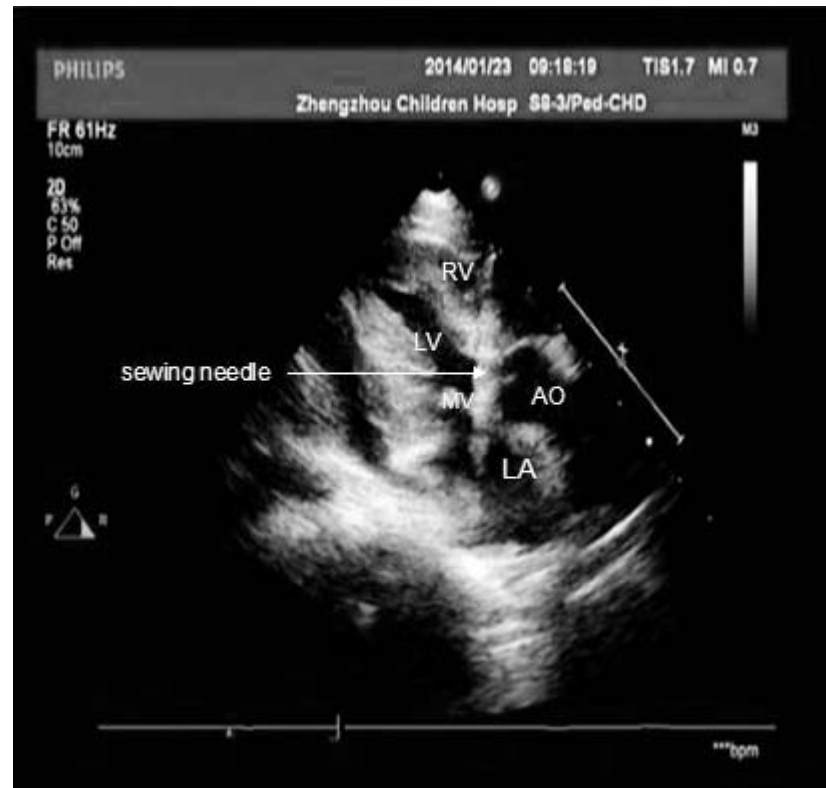

Fig. 2 Transthoracic echocardiography revealed a linear metallic foreign body within the heart. RV, right ventricle; LV, left ventricle; LA, left atrium; AO, aorta; MV, mitral valve.

successfully removed by catching it with a clamp from the left atrium (Fig. 3). Remarkable fibrous deposits could be seen in the heart around this needle and were removed during the surgery. The pericardium was irrigated with antibiotic solution. The operation was completed without any complication. Recovery was uneventful, and she was discharged 8 days after the surgery.

Discussion

In children, the injuries caused by sewing needles usually occur accidentally, except for some self-inflicted injuries caused by depressive behaviors^{1,2} or suicide attempts.³ Cases of child abuse have also been reported and were considered in this context.⁴ However, owing to the limited expressive abilities of children, it is typically challenging to elucidate the history of the injury. Therefore, clinical observation and early imaging studies of the needle are advocated. In our case, we still cannot distinguish whether the sewing needle was swallowed by the child or was inserted through the chest wall accidentally by herself or someone else.

The most common symptoms of cardiac FBs are cough, dyspnea, and chest pain, although it could be

asymptomatic in some cases. In most cases,^{5,6} early removal of the needle is recommended to prevent migration and further anatomic damage. However, it has also been reported that old wounds and asymptomatic foreign bodies with no associated risks may be treated conservatively, because with time, most FB become safely encysted and become benign.⁷ In our case, the results of echocardiogram indicated that mural thrombosis and pericardial effusion may have already developed in this patient, thus removal of the FB was determined to be the best approach to prevent further deterioration of the situation. The needle was removed after confirmation of its location and the surrounding anatomic structures by chest X-ray and echocardiogram.

The symptoms of the child in our case are not typical, which may be one of the major contributors to the delayed diagnosis of the FB. However, it is noteworthy that some of the symptoms, such as diarrhea and vomiting, may be caused by reasons other than cardiac FB, because a frequent incidence of diarrhea since birth has been proposed by her parents. Diarrhea could lead to electrolyte imbalance, which could cause convulsions.

Our case is unique in that it is still unknown when and how the sewing needle accessed the heart. We cannot determine the track of the sewing

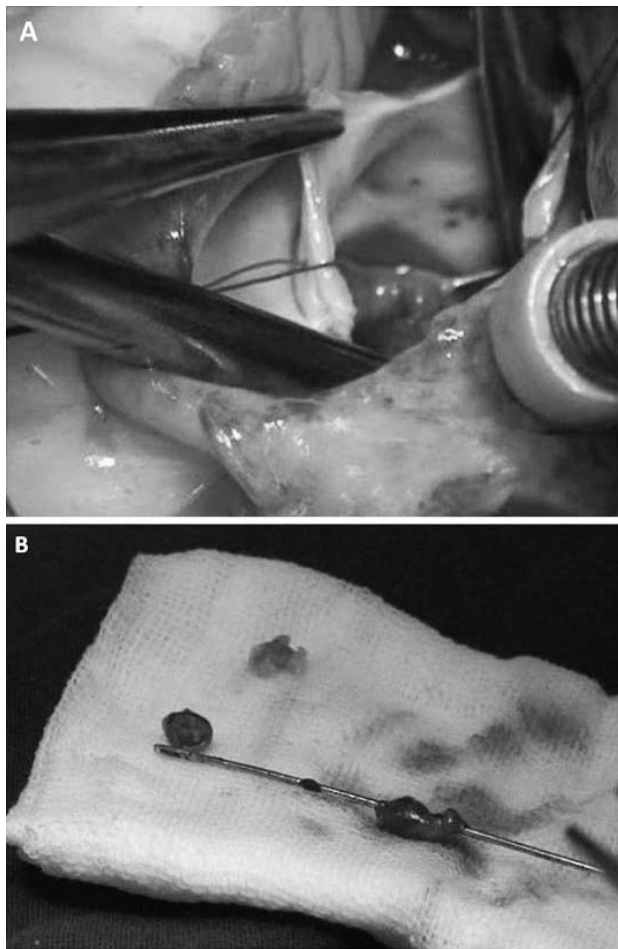


Fig. 3 Surgical procedures for the removal of the needle. (A) Needle located within left atrium extracted at sternotomy using a clamp. (B) Sewing needle was extracted from left atrium.

needle outside the heart. However, examinations during and after the surgery revealed no damage to the adjacent structures. Thus, we speculate that the sewing needle may have been located in the heart for a period of time, as the injured tissue around its tract required time to repair. In addition, the position of the sewing needle, which was located completely intracardiac rather than extracardiac, may have contributed to the reduction of the risk.

A 3-month follow-up revealed favorable recovery of the child, and almost all the symptoms had disappeared. Based on the above evidence, we

recommend that once an FB is found in the heart, it should be removed rather than leaving it untreated. Even if it is safely encysted and has lost the ability to migrate, the risk of mural thrombosis remains a threat. Also, infective endocarditis may develop in longstanding cases. Because of the risk of late complications, if the patient cannot tolerate surgery, a strict follow-up is necessary.

Acknowledgments

We declare that we have no conflicts of interest. Xiangyang Dong and Bo Zhai contributed equally to this manuscript.

References

1. Sayin AG, Besirli K, Arslan C, Canturk E. A case of intramyocardial sewing needle extracted without stopping the heart. *Injury* 2002;**33**(3):276–277
2. Baker CJ, Nigro JJ, Daggett CW, Wells WJ. Needle embolism to the heart. *Ann Thorac Surg* 2004;**77**(3):1102
3. Mihmanli I, Kurugoglu S, Kantarci F, Atakir K, Akman C. Intracardiac needle in a 12-year-old girl with self-injurious behavior. *Pediatr Radiol* 2002;**32**(3):109–110
4. Sola JE, Cateriano JH, Thompson WR, Neville HL. Pediatric penetrating cardiac injury from abuse: a case report. *Pediatr Surg Int* 2008;**24**(4):495–497
5. Talwar S, Subramaniam KG, Subramanian A, Kothari SS, Kumar AS. Sewing needle in the heart. *Asian Cardiovasc Thorac Ann* 2006;**14**(1):63–65
6. Inoue T, Iemura J, Saga T. Delayed cardiac tamponade caused by self-inserted needles. *Can J Cardiol* 2003;**19**(3):306–308
7. Perrotta S, Perrotta A, Lentini S. In patients with cardiac injuries caused by sewing needles is the surgical approach the recommended treatment? *Interact Cardiovasc Thorac Surg* 2010;**10**(5):783–792

© 2015 Dong et al.; licensee The International College of Surgeons. This is an Open Access article distributed under the terms of the Creative Commons Attribution Non-commercial License which permits use, distribution, and reproduction in any medium, provided the original work is properly cited, the use is non-commercial and is otherwise in compliance with the license. See: <http://creativecommons.org/licenses/by-nc/3.0>