

# How to Avoid Nontherapeutic Laparotomy in Patients With Multiple Organ Failure of Unknown Origin. The Role of CT Scan Revisited

Stephanie Li Sun Fui<sup>1</sup> Renato Micelli Lupinacci<sup>1</sup>, Christophe Trésallet<sup>1,2</sup>, Matthieu Faron<sup>1</sup>, Gaëlle Godiris-Petit<sup>1</sup>, Harika Salepcioglu<sup>1</sup>, Severine Noullet<sup>1</sup>, Fabrice Menegaux<sup>1,2</sup>

<sup>1</sup>*Department of General, Visceral, and Endocrine Surgery, Groupe Hospitalier Pitié-Salpêtrière, Assistance Publique – Hôpitaux de Paris (AP-HP), Paris, France*

<sup>2</sup>*Université Pierre et Marie Curie (Paris VI), Paris, France*

Diagnosis of intra-abdominal diseases in critically ill patients remains a clinical challenge. Physical examination is unreliable whereas exploratory laparotomy may aggravate patient's condition and delay further evaluation. Only a few studies have investigated the place of computed tomography (CT) on this hazardous situation. We aimed to evaluate the ability of CT to prevent unnecessary laparotomy during the management of critically ill patients. Charts of all consecutive patients who had undergone an emergency nontherapeutic laparotomy from 1996 to 2013 were retrospectively studied and patient's demographic, clinical characteristics, and surgical findings were collected. During this period 59 patients had an unnecessary laparotomy. Fifty-one patients had at least one preoperative imaging and 36 had a CT scan. CT scans were interpreted to be normal ( $n = 12$ ), with minor anomalies ( $n = 10$ ), or major anomalies (pneumoperitoneum, portal venous gas/pneumatosis intestinalis, thickened gallbladder wall, and small bowel obstruction signs). Surgical exploration was performed through laparotomy ( $n = 55$ ) or laparoscopy. Overall mortality was 37% with a median survival after surgery of 7 days. In univariate analysis, hospitalization in ICU before surgical exploration was the only factor related to death. In our series CT scans, objectively interpreted, helped avoid unnecessary surgical exploration in 61% of our patients.

*Key words:* Laparotomy – Critical care – Abnormalities – Digestive system – CT scans

Corresponding author : Renato Lupinacci, MD, Service de Chirurgie Générale, Hôpital de la Pitié, 47–83 Boulevard de l'hôpital, 75651 Paris Cedex 13, France.

Tel.: +33 01 42 17 66 32; Fax: +33 0 1 42 17 66 07; E-mail: renato.lupinacci@psl.aphp.fr

Early diagnosis of acute nontraumatic life-threatening intra-abdominal diseases remains a clinical challenge. In critically ill patients, pathologies such as mesenteric ischemia, intestinal perforation, pancreatitis and biliary diseases carry a high mortality rate ranging from 50% to 100%.<sup>1,2</sup> For these patients, physical examination can be unreliable due to deep sedation and absence of acute abdomen symptoms, and use of imaging studies may therefore be necessary to identify intra-abdominal pathologies and prevent delay in diagnosis. Also, imaging studies may help avoiding unnecessary laparotomy which can be associated with a morbidity rate up to 22%.<sup>3</sup> Ultrasonography (US) can be performed at the bedside and is a good alternative for the diagnosis of biliary tract disease; however, it is highly operator dependent, made difficult by abdominal distension,<sup>4</sup> and not effective for bowel perforation or ischemia.<sup>5</sup> Computed tomography (CT) scans are increasingly used for emergency patients with acute nontraumatic abdominal pain and tenderness, however, misinterpretation or overinterpretation of CT findings are not rare.<sup>6,7</sup> Despite the large use of imaging procedures in the evaluation of intra-abdominal pathologies, few studies have attempted to assess their impact on the management of critically ill patients.<sup>8,9</sup> The aim of this observational work was to evaluate the results of preoperative imaging procedures, especially CT, in a consecutive series of nontraumatic critically ill patients who underwent nontherapeutic surgical abdominal exploration in a French university tertiary care hospital.

## Patients and Methods

We retrospectively studied the charts of all consecutive patients who had undergone an emergency nontherapeutic surgical exploration at the Pitié Salpêtrière hospital, a French tertiary care center, from January 1996 to December 2013. Approval of the hospital's ethics committee was obtained prior to chart reviews. For all patients, the suspicion of intra-abdominal sepsis in the presence of multiple organ failure (MOF) served as the main indication for abdominal surgical exploration. Patients' demographic and clinical characteristics, admission diagnosis, surgical findings, and treatments administered after nontherapeutic laparotomy were collected. Organ dysfunction and organ failure were classified in accordance with previously published criteria<sup>10,11</sup> as follows: lung (pulmonary PaO<sub>2</sub>/FiO<sub>2</sub> ratio and/or

ventilator-dependence), heart (heart rate, arterial blood pressure, need for inotropic support, blood lactate levels), kidney (creatinine blood level and/or dialysis dependence), liver (liver function blood tests), central nervous system (encephalopathy), and gastrointestinal tract (digestive hemorrhage).

The decision whether to perform imaging studies preoperatively or to go straight to surgery depended on the medical team's (surgeons and intensivists) preference and the case particularities. Briefly, all patients had an abdominal and pelvic CT scan except those for whom intestinal ischemia and infarction was considered "absolutely certain" and for those who had another "contributory" imaging procedure (bedside US and/or X-ray). CT scans were reviewed by an experienced radiologist to confirm the described imaging findings. CT scans were interpreted as normal (no anomalies at all or the presence of a small to moderate amount of unexplained intraperitoneal fluid), with minor anomalies (isolated localized small bowel or colonic wall thickening, or nonspecific mesenteric infiltration), or with major anomalies (pneumoperitoneum, portal venous gas, pneumatosis intestinalis, thickened gallbladder wall with pericholecystic inflammation, or dilated, fluid-filled loops in the presence of collapsed loops compatible with small bowel obstruction).

Surgical findings, further explorations made postoperatively, and retained diagnoses were collected in order to establish, if possible, a final diagnosis. The relationship between mortality and preoperative factors were studied.

## Statistical analysis

Results are reported as median (range) or as mean  $\pm$  SD. Surviving and nonsurviving patient groups were compared using the  $\chi^2$  test or t test when appropriate. In order to find any predictive factor of mortality in this particular group of patients, univariate logistic regression analysis was used to estimate the relationship between mortality and the following variables: sex, age, comorbidities, preoperative imaging study, and patient origin (outpatients versus inpatients). Statistical significance was defined as  $P \leq 0.05$ . All analyses were performed using SAS computer software (SAS Institute Inc, Cary, NC).

## Results

During the study period, a total of 59 consecutive patients with MOF underwent a nontherapeutic

Table 1 Comorbid conditions of the 59 studied patients

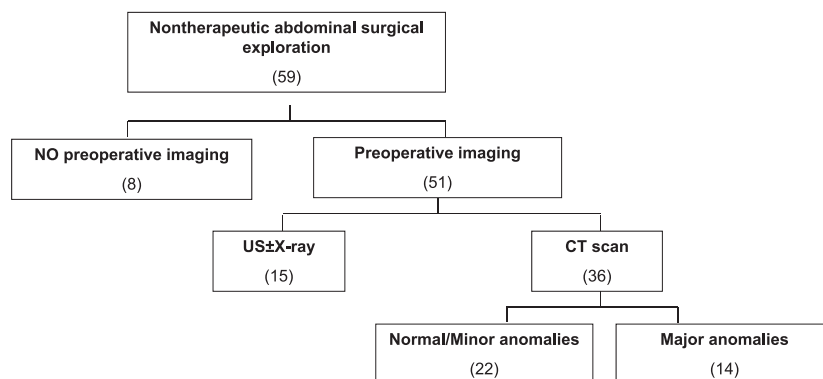
Comorbidities	No. of patients (%)
Malignancy	12 (20.3)
Immunodeficiency	9 (15.3)
Heart disease	22 (37.3)
Chronic renal insufficiency	7 (11.8)
Chronic respiratory insufficiency	8 (13.6)
Diabetes	14 (23.7)
Neuropsychiatric disorders	15 (25.4)
ischemic stroke	5
depression	4
others	6
Recent surgery	18 (30.5)
cardiovascular surgery	9
neurosurgery	2
digestive surgery	2
orthopaedic surgery	2
Chronic alcoholism	7 (11.8)
Obesity	4 (6.8)
Smoking	12 (20.3)
Lifetime treatment	30 (50.8)
corticosteroids	7
anticoagulant/antiplatelet	23

abdominal exploration. There were 26 men and 27 women with a median age of 63 years (range: 18–96 years). Nine (15%) patients were outpatients referred to our hospital's emergency room (ER) while 50 (85%) were inpatients at the time of surgery and were transferred to the operating room (OR) from the Intensive Care Unit (ICU;  $n = 27$ , 46%), or from the departments of Medicine ( $n = 15$ ) or Surgery ( $n = 8$ ). All patients had a least one comorbidity (Table 1), and 42% patients presented at least 3 chronic organ deficiencies or 2 organ deficiencies associated with malignancy, neuropsychiatric disorder, diabetes, or a risky lifetime treatment such as corticosteroids, anticoagulant, or antiplatelet therapy.

Fifty-one patients (86%) had preoperative imaging as summarized in Fig. 1. Fourteen patients had an abdominal X-ray, which was considered “clearly” pathologic in 5 patients (3 small bowel distensions, and 2 pneumoperitoneum case). Fifteen patients had a bedside US that was considered normal in 4 cases, showed some abdominal or pelvic fluid collection in 9 patients, revealed a thickened wall of the right colon in 1 patient, and gallbladder wall thickening associated with pericholecystic fluid in 1 patient. Twenty-three patients did not have a CT scan, mostly of them during the early period of this series. Among the 36 CT scans, 12 were interpreted as normal, 10 revealed only minor anomalies, and in the other 14 patients, a major anomaly was found: pneumoperitoneum in 6, portal venous gas in 3, pneumatosis intestinalis in 3, thickened gallbladder wall in 1, and small bowel obstruction signs in 1 patient.

Abdominal surgical exploration was performed through laparotomy (55/59, 93%) or laparoscopy (4/59). No acute intra-abdominal process was observed. The most common findings were the presence of serous or serous-sanguineous peritoneal fluid over 100 mL ( $n = 37$ ), or a localized small bowel or colonic wall thickening without ischemia ( $n = 6$ ). A sample of fluid was systematically sent to the laboratory for Gram stain and culture. In only 1 patient it revealed a bacterial contamination (*Escherichia coli*) of unknown origin.

Twenty-three (39%) patients had an additional procedure during surgical exploration. Cholecystectomy was performed in 9 patients (including the 2 patients with imaging findings of possible acute cholecystitis), and 14 patients had biopsies taken from the peritoneum ( $n = 5$ ), retroperitoneal lymph nodes ( $n = 1$ ), or liver ( $n = 8$ ). Tissue samples were contributory in 7 patients: 2 patients diagnosed with



**Fig. 1** Imaging studies performed before nontherapeutic laparotomy. \*5 patients had US and CT.

Table 2 Factors predicting death in 59 patients with nontherapeutic surgical exploration

Factor	Dead (n = 22)	Alive (n = 37)	P
Male-female ratio	10 – 12	19 – 17	0.66
Age, mean $\pm$ SD, years	67.8 $\pm$ 12.3	59.3 $\pm$ 23.6	0.075
Comorbidity			
Renal failure	4 (18%)	6 (16%)	0.85
Cardiac failure	12 (54%)	11 (30%)	0.059
Neurologic disease	5 (23%)	10 (27%)	0.71
Pulmonary disease	4 (18%)	6 (16%)	0.85
Diabetes	6 (27%)	9 (24%)	0.80
Malignancy	6 (27%)	6 (16%)	0.31
Immunodeficiency	7 (32%)	13 (35%)	0.79
Comorbidity ( $\geq 3$ )	8 (36%)	11 (30%)	0.60
Medical treatments			
Corticosteroids	4 (18%)	3 (8%)	0.41
Immunosuppressive treatment	1 (5%)	1 (3%)	1
Anticoagulant medication	5 (23%)	9 (24%)	0.89
Preoperative blood tests (mean $\pm$ SD)			
Creatinine level (mmol/L)	166 $\pm$ 92	225 $\pm$ 317	0.29
Hemoglobin (g/dL)	10.2 $\pm$ 2	11.1 $\pm$ 2.2	0.11
White blood cells (/mm <sup>3</sup> )	20400 $\pm$ 17600	14200 $\pm$ 8100	0.13
C-reactive protein (mg/L)	152 $\pm$ 61	120 $\pm$ 111	0.16
Glycemia (mmol/L)	7.5 $\pm$ 3.4	11 $\pm$ 10.2	0.06
Lactic acid (mmol/L)	2.8 $\pm$ 1.4	2.5 $\pm$ 1.3	0.42
Preoperative imaging procedures			0.80
No imaging procedure	4 (18%)	4 (11%)	
Preoperative US	5 (23%)	10 (27%)	
Preoperative CT	13 (59%)	23 (62%)	
Preoperative CT and/or US	16 (73%)	30 (81%)	0.45
Patient origin			0.04
Medicine Department	3	12	
Surgery Department	2	6	
ICU	12	9	
Emergency Department	1	8	

lymphoma, and 5 patients found out to have underlying cirrhosis. Review of preoperative CT scan of 1 patient diagnosed with intra-abdominal lymphoma actually showed multiple, round, enlarged lymph nodes with clear margins and uniform

density in the abdomen. Most importantly, in all but 1 patient surgical exploration did not help to establish the cause of MOF. This single patient was found to have end-stage liver disease and died 48 hours after surgery.

There were no complications related to surgical abdominal exploration. The overall mortality rate was 37% (22/53) with a median survival after surgery of 7 days (range: 0–37 days). The median length of stay in ICU for surviving patients was 12 days (range: 0–75 days). In univariate analysis, hospitalization in ICU before nontherapeutic surgical exploration was the only factor related to the risk of death (Table 2).

Although extensive diagnostic evaluation, final diagnosis could only be established in 32 patients (54%) as shown in Table 3. The most frequently retained cause of MOF were pneumonia (11 patients), acute heart failure (5 patients), and thermoregulation disorders (3 patients) during the 2003 European heat wave when France was hit especially hard.

Table 3 Final diagnosis of multiple organ failure

Diagnosis	Number of patients (%)
Digestive disorder	7 (12)
Infectious colitis	2
Digestive lupus erythematosus	2
End-stage liver disease	1
Gastric lymphoma	1
Small bowel ileus	1
Extra-abdominal etiology	25 (42)
Pneumonia	11
Acute heart failure	5
Thermoregulation disorders	3
Diabetic ketoacidosis	2
Septicemia of unknown origin	2
Pyogenic vertebral osteomyelitis	1
Pyelonephritis	1
No final diagnosis available	27 (46)

## Discussion

Our series confirmed that clinical presentation, physical examination, and blood tests are disappointing to discriminate surgical and nonsurgical causes of intra-abdominal sepsis in the presence of multiple organ failure. Evaluation of acute abdominal conditions in critically ill patients is often unreliable due to the patient's sedation and analgesic medication, inability to communicate, or intubation.<sup>5</sup> Delay in suspecting and diagnosing acute abdominal conditions can lead to serious and fatal consequences.<sup>5</sup> Over the past 30 years, CT has emerged as the technique of choice in most patients with acute abdomen. However, there is a lack of studies showing the overall impact of CT on the management of critically ill patients, and its capacity to avoid nontherapeutic surgical exploration.

In a previous report with 100 consecutive ICU patients who had laparotomy, surgery was considered not helpful in 27% of patients.<sup>12</sup> Moreover, nontherapeutic laparotomy has been associated with a morbidity rate up to 22%,<sup>3</sup> may aggravate patients' conditions, and may delay further evaluation. In the difficult clinical scenario of suspected intra-abdominal sepsis systematic CT scan may increase the physician's level of diagnostic certainty, rule out significant disorders by associating chest or other organ focused CT scan to the abdomino-pelvic scan, and provide an alternative diagnosis.

In our series, only 36 (61%) patients out of 59 had an abdominal and pelvic CT scan prior to surgery. It was mainly the consequence of decisions made upon clinical parameters and intensive care unit (ICU) course or the presence of abnormal findings in other imaging procedures (abdominal X-ray and US). Among these 36 patients, unnecessary surgical exploration could have been avoided in 22 (61%) patients without major anomalies found on CT. Noteworthy, CT scan was more frequently performed in the second period of the study and was part of the preoperative workup in all patients in the last 5 years ( $n = 12$ ).

Different groups have shown how the management of critically ill patients can be optimized by CT. Norwood and Civetta<sup>13</sup> showed CT scan to be useful to avoid nontherapeutic laparotomy in 23% of patients since localized abscesses were percutaneously drained and negative CT scans were not operated on. Also, in the study of Ahvenjärvi *et al*<sup>14</sup>, 61% of the CT performed led to a change of treatment, and 24% of them otherwise contributed to or supported clinical decision-making. As previ-

ously shown, clinical presentation, physical examination, and blood tests are disappointing to discriminate patients with intra-abdominal sepsis requiring surgery. An additional risk when one leads with critically ill patients is to deny a negative CT or to overestimate CT findings.<sup>5,15,16</sup>

Some authors advocate the use of bedside diagnostic laparoscopy for diagnosing abdominal diseases in ICU patients.<sup>5,17,18</sup> These studies reported a high diagnostic accuracy for intra-abdominal diseases, especially acute acalculous cholecystitis, but not for pancreatitis, retroperitoneal or inner-cavity diseases.<sup>19</sup> It is limited by the availability of an optimal operating-room-like environment in the ICU, and daily emergency and laparoscopic surgical technical skills of surgeons.<sup>18</sup> Complications rate reported ranges from 1% to 9%, and included visceral perforations, pneumoperitoneum-induced bradycardia, intraperitoneal hemorrhage and post-procedure ascitic leak from trocar site.<sup>18</sup> Also, bedside laparoscopy is contraindicated in case of endocranial hypertension or coagulopathy,<sup>5</sup> and may be hazardous in the presence of previous abdominal surgery (especially if major and/or recent), which was the case for 30% of our patients.

Bedside US is preferred for gallstone detection and is more useful in the initial evaluation of acute biliary disease than CT because ultrasound helps to screen patients who require further imaging from those who do not.<sup>20,21</sup> Eliciting a positive sonographic Murphy sign can help distinguish acute acalculous cholecystitis from a distended gallbladder caused by prolonged fasting, but it is important to remember that this sign may be masked by altered mental status or medications.<sup>21</sup> Also, thickening of the gallbladder wall in the absence of cholecystitis may be observed in systemic conditions, such as liver, renal, and heart failure, possibly due to elevated portal and systemic venous pressures.<sup>22</sup> Furthermore, although CT is inferior to ultrasound for the detection of gallstones in the gallbladder, it is the best technique for imaging complicated gallbladder disease such as emphysematous cholecystitis.<sup>21</sup>

Recently, Chen *et al* evaluated the role of gallium-67 scintigraphy in the evaluation of occult sepsis in ICU. Although it helped to detect new or additional infectious sites, particularly bone, joint, and soft tissues, differences in hospital stay and mortality were not observed between patients with positive and negative findings.<sup>23</sup> Therefore, this procedure cannot be routinely recommended.

A normal CT or even the presence of minor anomalies in CT (unexplained peritoneal fluid, isolated localized small bowel or colonic wall thickening, mesenteric infiltration) should not lead to surgical exploration of the abdomen before an extensive assessment to try to elucidate the aggravation or the severity of patient's clinical condition. The issue is different in patients who present a major anomaly on CT. In our series, 14 patients had a major anomaly such as pneumoperitoneum, gas in portal venous system, pneumatosis intestinalis, and typical signs of acute cholecystitis or small bowel obstruction found on CT. In such cases, surgical abdominal exploration is highly recommended.

Incidents related to transport of critically ill patients have been extensively reported and remain a major issue. Beckmann's study reports that the majority of equipment- and organization-related incidents occur during the transfer from ICU to radiology or the operating theater for diagnostic testing.<sup>24</sup> Communication between ICU and sites of destination or origin is vital for reducing waiting time and therefore transport time.<sup>25</sup> Also, a preventive program applied by all care providers involved in transport of critically ill patients may be associated with a 20% absolute reduction of incidents.<sup>26</sup> Moreover, modern CT scanners are so fast that they can scan through large sections of the body in just a few seconds, which is beneficial for all patients but especially children, the elderly, and critically ill.

Our study has several limitations. First, this article does not address the issue of the performance of CT in critically ill patients with suspected intra-abdominal sepsis. The goal of this study was to describe the patterns and outcome of patients who had a negative surgical abdominal exploration. Second, this is a retrospective study covering a relatively long period of time (1996–2013), where improvements in imaging may have resulted in differences in the likelihood of eliminating intra-abdominal pathologies.

In conclusion, there is a lack of studies showing the overall impact of imaging tests on the management of critically ill patients. It can be helpful in the case of patients with inconclusive findings on other imaging modalities and help avoiding non therapeutic surgical exploration when carefully and objectively interpreted.

## Acknowledgments

The authors have no conflict of interest to declare. No financial support was received in any form.

Stephanie Li Sun Fui and Renato Micelli Lupinacci contributed equally to this manuscript. The authors wish to thank the following individuals for their respective contributions. For study concept and design, C Trésallet and F Menegaux; for data acquisition, S Li Sun Fui, G Godiris-Petit, M Faron, H Salepcioglu, and S Noulet; for data analysis and interpretation, S Li Sun Fui, RM Lupinacci, M Faron, C Trésallet, and F Menegaux; for statistical analysis, M Faron, RM Lupinacci, G Godiris-Petit, H Salepcioglu, S Noulet, and F Menegaux; for manuscript preparation and editing, S Li Sun Fui, RM Lupinacci, and C Trésallet; and for manuscript review and final approval, S Li Sun Fui, RM Lupinacci, M Faron, C Trésallet, G Godiris-Petit, H Salepcioglu, S Noulet, and F Menegaux. Statistical analysis was checked by Dr Matthieu Faron, MD, MSc, (MD MSc) who has a masters in Biostatistics and is currently doing a PhD in Oncology/Biostatistics.

## References

1. McKinsey JF, Gewertz BL. Acute mesenteric ischemia. *Surg Clin North Am* 1997; **77**(2):307–325
2. Barie PS, Fischer E. Acute acalculous cholecystitis. *J Am Coll Surg* 1995; **180**(2):232–276
3. Memon MA, Fitzgibbons RJ Jr. The role of minimal access surgery in the acute abdomen. *Surg Clin North Am* 1997; **77**(6): 1333–1386
4. Wang HP, Chen SC. Upper abdominal ultrasound in the critically ill. *Crit Care Med* 2007; **35**(5 Suppl):S208–S223
5. Ceribelli C, Adami EA, Mattia S, Benini B. Bedside diagnostic laparoscopy for critically ill patients: a retrospective study of 62 patients. *Surg Endosc* 2012; **26**(12):3612–3617
6. Krajewski S, Brown J, Phang PT, Raval M, Brown CJ. Impact of computed tomography of the abdomen on clinical outcomes in patients with acute right lower quadrant pain: a meta-analysis. *Can J Surg* 2011; **54**:43–53
7. Broder JS, Hollingsworth CL, Miller CM, Meyer JL, Paulson EK. Prospective double-blinded study of abdominal-pelvic computed tomography guided by the region of tenderness: estimation of detection of acute pathology and radiation exposure reduction. *Ann Emerg Med* 2010; **56**:126–160
8. Rosen MP, Sands DZ, Longmaid HE 3<sup>rd</sup>, Reynolds KF, Wagner M, Raptopoulos V. Impact of abdominal CT on the management of patients presenting to the emergency department with acute abdominal pain. *AJR Am J Roentgenol* 2000; **174**(5):1391–1397
10. Hill BC, Johnson SC, Owens EK, Gerber JL, Senagore AJ. CT scan for suspected acute abdominal process: impact of combinations of IV, oral, and rectal contrast. *World J Surg* 2010; **34**(4):699–703

11. Goris RJA, te Boekhorst TPA, Nuytinck JKS, Gimbrère JSF. Multiple-organ failure. Generalized autodestructive inflammation? *Arch Surg* 1985;**120**:1109–1124
12. Sauaia A, Moore EE, Johnson JL, Ciesla DJ, Biffl WL, Banerjee A. Validation of post-injury multiple organ failure scores. *Shock* 2009;**31**:438–485
13. Sutherland FR, Temple WJ, Snodgrass T, Huchcroft SA. Predicting the outcome of exploratory laparotomy in ICU patients with sepsis or organ failure. *J Trauma* 1989;**29**(2):152–159
14. Norwood SH, Civetta JM. Abdominal CT scanning in critically ill surgical patients. *Ann Surg* 1985;**202**(2):166–175
15. Ahvenjärvi LK, Laurila JJ, Jartti A, Ylipalosaari P, Ala-Kokko TI, Syrjälä HP. Multi-detector computed tomography in critically ill patients. *Acta Anaesthesiol Scand* 2008;**52**:547–599
16. Kelly JJ, Puyana JC, Callery MP, Yood SM, Sandor A, Litwin DE. The feasibility and accuracy of diagnostic laparoscopy in the septic ICU patient. *Surg Endosc* 2000;**14**:617–621
17. Ferraris VA. Exploratory laparotomy for potential abdominal sepsis in patients with multiple-organ failure. *Arch Surg* 1983;**118**(10):1130–1133
18. Brandt CP, Priebe PP, Eckhauser ML. Diagnostic laparoscopy in the intensive care patient. Avoiding the nontherapeutic laparotomy. *Surg Endosc* 1993;**7**:168–240
19. Peris A, Matano S, Manca G, Zagli G, Bonizzoli M, Cianchi G *et al.* Bedside diagnostic laparoscopy to diagnose intra-abdominal pathology in the intensive care unit. *Crit Care* 2009;**13**(1):R25
20. Stefanidis D, Richardson WS, Chang L, Earle DB, Fanelli RD. The role of diagnostic laparoscopy for acute abdominal conditions: an evidence-based review. *Surg Endosc* 2009;**23**(1):16–23
21. Harvey RT, Miller WT Jr. Acute biliary disease: initial CT and follow-up US versus initial US and follow-up CT. *Radiology* 1999;**213**:831–836
22. O'Connor OJ, Maher MM. Imaging of cholecystitis. *AJR Am J Roentgenol* 2011;**196**(4):W367–441
23. van Breda Vriesman AC, Engelbrecht MR, Smithuis RH, Puylaert JB. Diffuse gallbladder wall thickening: differential diagnosis. *AJR Am J Roentgenol* 2007;**188**(2):495–501
24. Chen WC, Tsai KD, Chen CH, Lin MS, Chen CM, Shih CM *et al.* Role of gallium-67 scintigraphy in the evaluation of occult sepsis in the medical ICU. *Intern Emerg Med* 2012;**7**(1):53–61
25. Beckmann U, Gillies DM, Berenholtz SM, Wu AW, Pronovost P. Incidents relating to the intra-hospital transfer of critically ill patients. An analysis of the reports submitted to the Australian Incident Monitoring Study in Intensive Care. *Intensive Care Med* 2004;**30**(8):1579–1585
26. Fanara B, Manzon C, Barbot O, Desmettre T, Capellier G. Recommendations for the intra-hospital transport of critically ill patients. *Crit Care* 2010;**14**(3):R87
27. Bérubé M, Bernard F, Marion H, Parent J, Thibault M, Williamson DR *et al.* Impact of a preventive programme on the occurrence of incidents during the transport of critically ill patients. *Intensive Crit Care Nurs* 2013;**29**(1):9–19