



# The Management of Varicose Veins

Fan Lin<sup>1</sup>, Shiyi Zhang<sup>2</sup>, Yan Sun<sup>2</sup>, Shiyan Ren<sup>1</sup>, Peng Liu<sup>1</sup>

<sup>1</sup>Department of Vascular Surgery, China-Japan Friendship Hospital No. 2, Yinghua yuan East Road, Beijing, China

<sup>2</sup>Department of Vascular Surgery, Shandong Provincial Hospital, Shandong University, Jinan Shandong, China

**This study aimed to review the current management modalities for varicose veins. There are a variety of management modalities for varicose veins. The outcomes of the treatment of varicose veins are different. The papers on the management of varicose veins were reviewed and the postoperative complications and efficacy were compared. Foam sclerotherapy and radiofrequency ablation were associated with less pain and faster recovery than endovenous laser ablation and surgical stripping. Patients undergoing endovenous laser ablation and radiofrequency ablation are most likely to have a faster recovery time and earlier return to work in comparison with those undergoing conventional high ligation and stripping. A randomized controlled study in multiple centers is warranted to verify which approach is better than others for the treatment of varicose veins.**

Varicose veins are dilated branches of the great saphenous vein and small saphenous vein; the incidence of varicose veins varies from 10% to 30%.<sup>1</sup> Risk factors of varicose veins include family history, age, and pregnancy; a possible risk factor is standing for a long period of time.<sup>1–3</sup> High ligation and stripping is the traditional approach for varicose veins, yet a variety of alternative options have been used in recent decades, such as endovenous laser ablation (EVLA), endovenous radiofrequency ablation (RFA), foam sclerotherapy (FS), or TriVex.<sup>4–7</sup>

## Manifestation and Severity of Varicose Veins

Patients with varicose veins present from asymptomatic to significant symptoms, including discomfort, aching, pain, itching or eczema, and deep vein thrombosis (DVT).<sup>8</sup> The diagnosis of varicose veins is based on clinical manifestation and ultrasound. Duplex ultrasound is considered the gold standard for diagnosis of superficial venous incompetence. The CEAP (clinical, etiology, anatomy, pathophysiology) classification is used to describe the degree of varicose veins. The “C” part of CEAP classification

Corresponding authors: Shiyan Ren and Peng Liu, Department of Vascular Surgery, China-Japan Friendship Hospital No. 2, Yinghua yuan East Road, Chaoyang District, Beijing 100029, China.  
Tel.: 86 10 13661004048; E-mail: rens66@126.com

Table 1 CEAP classification: C (clinical component)

C0	No visible or palpable signs of venous disease
C1	Telangiectases (dilated interdermal venules <1 mm) or reticular veins (nonpalpable subdermal veins 1–3 mm)
C2	Varicose veins (diameter of vein >3 mm)
C3	Edema
C4a	Pigmentation or eczema
C4b	Lipodermatosclerosis
C5	Healed venous ulcer
C6	Active venous ulcer

is more useful and practical in rating the severity of varicose veins (Table 1).<sup>9</sup> Venous clinical severity scoring has been used to measure clinical improvement after treatment of varicose veins.<sup>9,10</sup> Preoperative venous duplex ultrasound is used to evaluate patients for venous insufficiency symptoms or suspected DVT; it can provide a road map of vein anatomy similar to contrast venography, as well as essential hemodynamic information about the presence of proximal obstruction, vein valve function, and venous reflux.

### Indication and Contraindication of Treatment for Varicose Veins

The purpose of treatment is to relieve symptoms and prevent the progression of varicose veins.<sup>4,8</sup> Symptomatic patients with C2 to C6 diseases are indicated for management, especially those who have signs of chronic venous insufficiency, superficial thrombophlebitis, and bleeding.

Asymptomatic patients can be observed and do not need treatment or prophylactic intervention.<sup>11</sup> However, cosmesis is a common reason for treatment of asymptomatic patients, especially for young female patients. It is controversial to perform surgery on patients who have recovered from the superficial phlebitis,<sup>11</sup> because the dilated varicose veins usually disappeared without further surgical treatment. It is not indicated to perform thrombectomy for superficial thrombosis in great saphenous veins. The patients should be educated prior to surgery that varicose vein surgery is not curative, and early surgery in uncomplicated veins will not prevent the development of future varicosities.

The contraindications for surgical management of varicose veins are occlusion of the deep venous system, such as acute DVT,<sup>11</sup> pregnancy, the superficial veins as collaterals for occluded deep veins, and arterial insufficiency; however, one should proceed with caution in performing surgery on patients with postthrombotic syndrome, venous

Table 2 Complications after different modalities for varicose veins

Postoperative complications	Incidence
CS	
5-y recurrence after CS in GSV	13%–29% <sup>24</sup>
>30-y recurrence after CS in GSV	60% <sup>25</sup>
5-y recurrence after CS in SSV	30% <sup>5</sup>
Saphenous nerve damage after stripping (groin-knee level)	8% <sup>26</sup>
Saphenous nerve damage after stripping (groin-ankle level)	40% <sup>20</sup>
Sural nerve injury/paraesthesia after CS in SSV	1.7%–34% <sup>5</sup>
DVT after CS in GSV	5.3% <sup>15</sup>
EVLA	
DVT in GSV	1% <sup>5</sup>
DVT in LSV	1.3%–5.7% <sup>16</sup>
FS	
Thromboembolic complication	0.40% <sup>27</sup>
Visual disturbance	0.40% <sup>27</sup>

CS, conventional surgery; GSV, great saphenous vein; LSV, less saphenous vein; SSV, small saphenous vein.

refluxing combined with arterial venous fistula, or venous malformation—further imaging to assess the patency of the deep veins is critical before surgery. Emergent management is usually reserved for bleeding varicosities or suspected DVT.

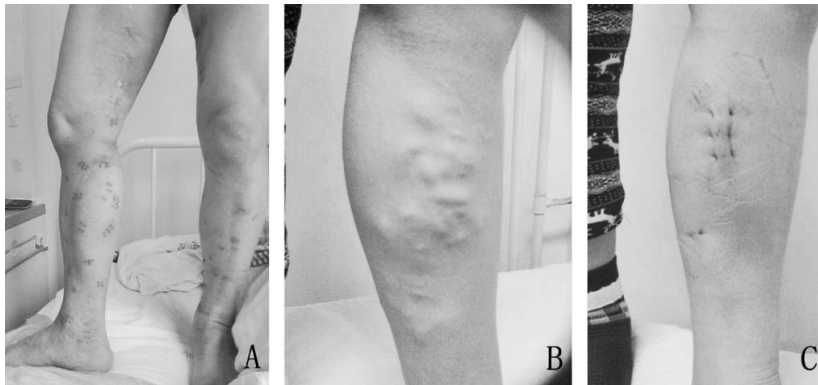
### Modalities for Management of Varicose Veins

#### Conventional surgical stripping

All management modalities for varicose veins are safe and effective at short-term and midterm follow-up.<sup>11</sup> The methods to manage great saphenous veins traditionally include ligation and division of the saphenofemoral junction and its tributaries in the groin, stripping the great saphenous veins from groin to knee level. The incompetent small saphenous veins are ligated and divided, rather than stripped, close to the popliteal vein in the knee pit, because stripping small saphenous veins may potentially damage the sural nerve.<sup>11</sup> It is not rare for recurrence, hematoma, and skin infection to occur after surgical procedure (Table 2). And massive bleeding due to injury to femoral veins, or even to femoral artery during surgery, and mortality from pulmonary embolism and DVT can happen, even though these are rarely reported.

#### Endovenous thermoablation

Endovenous thermoablation approaches include EVLA and radiofrequency ablation; these belong to the category of minimally invasive catheter-based procedures.<sup>3</sup> In this procedure, a catheter is inserted



**Fig. 1** Comparison of postoperative outcomes after conventional surgical stripping (A) with FS (B and C). Multiple surgical scars seen after surgical stripping (A); no visible varicose veins seen 4 days after FS (C) versus obvious varicose veins prior to FS.

and positioned at 2 cm below the saphenofemoral or saphenopopliteal junction. Local anesthesia is used with perivenous tumescent technique to prevent neural damage and skin burn. Alternatively, venous sedation can be used. The thermal energy is delivered onto the diseased venous wall and induces inflammation response and subsequent fibrosis and closure of the vein.<sup>7</sup>

Faster recovery from EVLA, no need for hospital admission, no surgical incision, and early resumption of daily activity or work are advantages of this procedure. However, like other surgeries, EVLA still can cause operative or postoperative complications, such as hematoma, infection, skin burn, bruising, and catheter stabbing by laser fiber, or the broken catheter can be left in the body.<sup>3,12,13</sup> Many clinical studies and randomized controlled trials of high quality compared EVLA and conventional surgical procedures and showed no differences in postoperative pain, recurrence rates, or returning to work or normal activity.<sup>7,14</sup>

Clinical experience shows that the pain after laser ablation contributes to the skin contusion caused between skin and uneven bandages used after the procedure, blisters induced by skin burn, and endovenous thermal-induced thrombosis and thrombophlebitis<sup>7</sup>; all of these problems can be prevented with careful manipulation during the procedure. Using proper compression stocking rather than bandage may reduce the risk of skin contusion. In addition, early ambulation is always critical to preventing DVT.<sup>11,15</sup>

#### *Radiofrequency ablation*

The technique of endovenous RFA has been available since 1998; it delivers thermal energy from a bipolar catheter to the insufficient veins. RFA is an effective and safe treatment modality for incompe-

tent veins, and it can be performed in-office as a minimally invasive procedure. The advantages of RFA include low complication rate, reduced pain, high vein occlusion rates, and early return to work and normal activities.

Currently available clinical trial evidence suggests RFA and EVLA are at least as effective as surgery in the treatment of great saphenous varicose veins.<sup>7,11,16</sup>

#### *Foam sclerotherapy*

Sclerosing foam is injected through a cannula in the vein under duplex ultrasound guidance; it can be undertaken in the outpatient clinic, and a compression stocking should be used immediately after FS.<sup>17</sup> Observational studies found that success rates vary from 82% to 100%,<sup>5</sup> and the recovery was faster following FS than following conventional surgical stripping. It takes approximately 1 hour to perform FS, patients do not need to take medicine or stay in the hospital, and patients can go home or continue to work immediately after the procedure. The efficacy of FS is obvious in comparison with conventional surgical stripping (Fig. 1). Complications after FS are rare, including bruising, thrombophlebitis, skin pigmentation, and visual disturbance.<sup>18</sup>

#### *Ambulatory phlebectomy*

Ambulatory phlebectomy is an outpatient procedure that removes superficial veins through small 2- to 3-mm incisions in the skin overlying the varicose veins and is performed under local anesthesia. The accepted indications for this technique are side branch varicose veins, and varicose veins of the foot, around the ankle, and the knee pit. The most important instrument for this technique is the vein retractor or phlebectomy hook. There are two ways

by which the veins can be grasped. The phlebectomy hook is inserted through an incision and the varicose vein is hooked, extracted, and subsequently fixed with a clamp; the vein is finally pulled out by turning the exteriorized part of the vein. Graded compression stockings or compression bandages are usually used for 1 to 2 weeks after the procedure. This procedure is often used as an adjunct to EVLA or RFA, either concomitantly or in the sequential management of tributaries for symptomatic varicose veins. The complications are uncommon but include paresthesia, bruising, hemorrhage, and hematoma. EVLA with both treatments achieves excellent results at 5 years. Concomitant treatment of varicosities is associated with optimal improvement in both clinical disease severity and quality of life.<sup>19,20</sup>

### Superficial and Deep Venous Insufficiency

It is not rare to see patients with both superficial and deep venous insufficiency. The most common cause is the valve insufficiency of the deep veins due to DVT; in rare conditions it can be due to congenital valve or vessel abnormalities. Venous reflux increases the risk of developing varicose veins, especially in cases of combined deep and superficial reflux.<sup>19</sup> An incompetent vessel due to venous refluxing is itself unnecessary and useless because it is carrying venous blood in a retrograde direction and causes symptoms. Graduated compression has been proven useful in managing venous insufficiency. Refluxing superficial vessels can safely be ablated or stripped. Surgical or endovenous therapy is commonly reserved for patients with discomfort or ulcers refractory to medical treatment. Successful management of superficial venous refluxing only is helpful in reducing the symptoms of deep venous refluxing. External valvuloplasty, such as external vein valve wrapping, is a reconstructive surgical modality preferred in cases with dilation and reflux due to valve incompetency.<sup>19</sup> It aims to increase the coating surface and restore valve competency by external support<sup>22</sup> and has not gained large popularity due to its efficacy. However, some experts recommend external valvuloplasty for venous refluxing because it can be at least comparable to or probably better than conventional ligation and stripping.<sup>23</sup>

Overall, all management modalities appear to be safe and effective in the short term and midterm,<sup>11</sup> and it is equally true that no procedures for varicose veins have no side effects during or after the procedure. Current studies showed that FS and

RFA were associated with less pain and faster recovery than EVLA and surgical stripping; EVLA and RFA have shown faster recovery and earlier return to work in comparison with conventional high ligation and stripping. FS was associated with the highest failure rate.<sup>7,14</sup> However, high-quality randomized controlled trials in multiple medical centers with long-term follow-up are warranted before endovenous management is considered as the first choice for varicose veins.

### Acknowledgments

The first three authors (FL, YS, SZ) contributed equally to this article.

### References

1. Evans CJ, Fowkes FG, Ruckley CV, Lee AJ. Prevalence of varicose veins and chronic venous insufficiency in men and women in the general population: Edinburgh Vein Study. *J Epidemiol Community Health* 1999;**53**(3):149–153
2. Ren S, Liu P, Zou N, Tan X. Better outcomes of varicose veins with EVLT alone than in combination with Trivex by GRA. *J Grey Syst* 2008;**20**(3):195–204
3. Liu P, Ren S, Yang Y, Liu J, Ye Z, Lin F. Intravenous catheter-guided laser ablation: a novel alternative for branch varicose veins. *Int Surg* 2011;**96**(4):331–336
4. Biemans AA, Kockaert M, Akkersdijk GP, van den Bos RR, de Maeseneer MG, Cuypers P *et al.* Comparing endovenous laser ablation, foam sclerotherapy, and conventional surgery for great saphenous varicose veins. *J Vasc Surg* 2013;**58**(3):727–734.e1
5. Tellings SS, Ceulen RP, Sommer A. Surgery and endovenous techniques for the treatment of small saphenous varicose veins: a review of the literature. *Phlebology* 2011;**26**(5):179–184
6. Bush RG, Hammond K. Treatment of incompetent vein of Giacomini (thigh extension branch). *Ann Vasc Surg* 2007;**21**(2):245–248
7. Rasmussen LH, Lawaetz M, Bjoern L, Vennits B, Blemings A, Eklof B. Randomized clinical trial comparing endovenous laser ablation, radiofrequency ablation, foam sclerotherapy and surgical stripping for great saphenous varicose veins. *Br J Surg* 2011;**98**(8):1079–1087
8. Ren S, Liu P. Initial clinical experiences in treating 27 cases of varicose veins with EVLT plus TRIVEX. *J US China Med Sci* 2005;**2**(1):4–8
9. Vasquez MA, Munschauer CE. Venous Clinical Severity Score and quality-of-life assessment tools: application to vein practice. *Phlebology* 2008;**23**(6):259–275

10. Lattimer CR, Kalodiki E, Azzam M, Geroulakos G. The Aberdeen varicose vein questionnaire may be the preferred method of rationing patients for varicose vein surgery. *Angiology* 2014;**65**(3):205–209
11. van den Boezem PB, Klem TM, le Cocq d'Armandville E, Wittens CH. The management of superficial venous incompetence. *BMJ* 2011;**343**:d4489
12. Ren S, Liu P, Wang W, Yang Y. Retained foreign body after laser ablation. *Int Surg* 2012;**97**(4):293–295
13. van den Bos RR, Neumann M, Nijsten T. Laser fibre stabs the catheter: a serious complication of endovenous laser ablation. *Phlebology* 2011;**26**(3):119–120
14. Bountouroglou DG, Azzam M, Kakkos SK, Pathmarajah M, Young P, Geroulakos G. Ultrasound-guided foam sclerotherapy combined with sapheno-femoral ligation compared to surgical treatment of varicose veins: early results of a randomised controlled trial. *Eur J Vasc Endovasc Surg* 2006;**31**(1):93–100
15. van Rij AM, Chai J, Hill GB, Christie RA. Incidence of deep vein thrombosis after varicose vein surgery. *Br J Surg* 2004;**91**(12):1582–1585
16. Almeida JL, Raines JK. Radiofrequency ablation and laser ablation in the treatment of varicose veins. *Ann Vasc Surg* 2006;**20**(4):547–552
17. Gloviczki P, Gloviczki ML. Guidelines for the management of varicose veins. *Phlebology* 2012;**27**(suppl 1):2–9
18. Willenberg T, Smith PC, Shepherd A, Davies AH. Visual disturbance following sclerotherapy for varicose veins, reticular veins and telangiectasias: a systematic literature review. *Phlebology* 2013;**28**(3):123–131
19. Harlander-Locke M, Jimenez JC, Lawrence PF, Derubertis BG, Rigberg DA, Gelabert HA. Endovenous ablation with concomitant phlebectomy is a safe and effective method of treatment for symptomatic patients with axial reflux and large incompetent tributaries. *J Vasc Surg* 2013;**58**(1):166–172
20. Carroll C, Hummel S, Leaviss J. Systematic review, network meta-analysis and exploratory cost-effectiveness model of randomized trials of minimally invasive techniques versus surgery for varicose veins. *Br J Surg* 2014;**101**(9):1040–1052
21. Robertson LA, Evans CJ, Lee AJ, Allan PL, Ruckley CV, Fowkes FG. Incidence and risk factors for venous reflux in the general population: Edinburgh Vein Study. *Eur J Vasc Endovasc Surg* 2014;**48**(2):208–214
22. Belcaro G, Nicolaides AN, Lennox A. Tissue response to an expanded polytetrafluoroethylene external valve support device: a histologic study in dogs. *Angiology* 2000;**51**(8, Pt 2): S33–S38
23. Sarac A, Jahollari A, Talay S, Ozkaya S, Ozal E. Long-term results of external valvuloplasty in adult patients with isolated great saphenous vein insufficiency. *Clin Interv Aging* 2014;**9**: 575–579
24. Dwerryhouse S, Davies B, Harradine K, Earnshaw JJ. Stripping the long saphenous vein reduces the rate of reoperation for recurrent varicose veins: five-year results of a randomized trial. *J Vasc Surg* 1999;**29**(4):589–592
25. Fischer R, Linde N, Duff C, Jeanneret C, Chandler JG, Seeber P. Late recurrent saphenofemoral junction reflux after ligation and stripping of the greater saphenous vein. *J Vasc Surg* 2001;**34**(2):236–240
26. Subramonia S, Lees T. Sensory abnormalities and bruising after long saphenous vein stripping: impact on short-term quality of life. *J Vasc Surg* 2005;**42**(3):510–514
27. Bradbury AW, Bate G, Pang K, Darvall KA, Adam DJ. Ultrasound-guided foam sclerotherapy is a safe and clinically effective treatment for superficial venous reflux. *J Vasc Surg* 2010;**52**(4):939–945